

eMedicine Specialties > Dermatology > Diseases of the Oral Mucosa

Necrotizing Sialometaplasia

John Svirsky, DDS, Director of Dental Diagnostic Services, Professor, Department of Oral Pathology, Virginia Commonwealth University School of Dentistry

John E Fantasia, DDS, Attending, Chief, Division of Oral Pathology, Department of Dermatology, Long Island Jewish Medical Center, North Shore - Long Island Jewish Health System; **Josephine Wu, DDS**, Assistant Director, Molecular Pathology Laboratory, Department of Pathology, Mount Sinai School of Medicine, Consulting Staff, Division of Oral and Maxillofacial Pathology, Department of Dental Medicine, Long Island Jewish Medical Center

Updated: Oct 28, 2008

Introduction

Background

Necrotizing sialometaplasia (NS) is a nonneoplastic inflammatory condition of the salivary glands. In 1973, Abrams et al first reported this condition.¹ The clinical and histopathologic features of necrotizing sialometaplasia often simulate those of malignancies such as squamous cell carcinoma or salivary gland malignancy.² All subsequent reports of necrotizing sialometaplasia stress the importance of correct diagnosis. Familiarity with necrotizing sialometaplasia and correct diagnosis are paramount in avoiding misdiagnosis and inappropriate treatment. Ischemia of salivary gland tissue leading to infarction (trauma) is the most likely cause.

A related eMedicine article that may be of interest is [Cancers of the Oral Mucosa](#).

Pathophysiology

Necrotizing sialometaplasia was first reported to involve the minor salivary glands of the oral cavity, particularly those of the palate. Seventy-five percent of all cases occur on the posterior palate.³ Most are unilateral, with one third occurring in a bilateral or midpalatal location. Reports of this entity in the minor glands of the retromolar pad area, buccal mucosa, tongue, incisive canal, and labial mucosa followed. In addition, necrotizing sialometaplasia is recognized in the parotid and submandibular salivary glands,⁴ minor mucous glands in the lung,⁵ nasal cavity,^{6,7} larynx,^{8,9} trachea,¹⁰ nasopharynx, and maxillary sinus.¹¹ Similar lesions are identified in the breast; the condition is referred to as posttraumatic lobular metaplasia of the breast.¹²

Frequency

United States

Mesa and colleagues reported an incidence of 0.03% based on findings in 10,000 oral biopsy specimens.¹³ However, they state that this percentage does not account for cases of necrotizing sialometaplasia that heal spontaneously without biopsy.

International

Necrotizing sialometaplasia is reported worldwide. Isolated cases and reviews from Europe, North America, South America, and Asia are reported in the literature.

Mortality/Morbidity

The lesions of necrotizing sialometaplasia often are painless; less frequently, they cause pain and numbness. The clinical appearance that suggests cancer is the significant feature of this lesion. The clinical pictures show a patient with a lesion thought to be cancer who underwent biopsy and was monitored for 9 weeks. Over that time, regression of the lesion can be seen (see Media Files 1-4).

Race

- Brannon and colleagues¹⁴ reported that cases of necrotizing sialometaplasia in whites outnumbered cases in blacks by a ratio of 4.9:1.
- Given the ratio of whites to blacks in the United States, a significant racial predilection does not appear to exist.

Sex

- The male-to-female ratio is approximately 2:1.

Age

- The average age of patients
walmart da Windows Internet Explorer 8> Subject: Necrotizing
Sialometaplasia: [Print] - eMedicine Dermatology Date: Fri, 4 Sep 2009 01:24:22 +0200 MIME-Version: 1.0
Content-Type: multipart/related; type="text/html"; boundary="----
=_NextPart_000_048C_01CA2CFE.6EBAC650" X-MimeOLE: Produced By Microsoft MimeOLE
V6.00.2900.5579 This is a multi-part message in MIME format. -----
=_NextPart_000_048C_01CA2CFE.6EBAC650 Content-Type: text/html; charset="Windows-1252"
Content-Transfer-Encoding: quoted-printable Content-Location:
<http://emedicine.medscape.com/article/1077574-print>



emedicine.medscape.com

eMedicine Specialties > Dermatology > Diseases of the Oral Mucosa

Necrotizing Sialometaplasia

John Svirskey, DDS, Director of Dental Diagnostic Services, Professor, Department of Oral Pathology, Virginia Commonwealth University School of Dentistry

John E Fantasia, DDS, Attending, Chief, Division of Oral Pathology, Department of Dermatology, Long Island Jewish Medical Center, North Shore - Long Island Jewish Health System; **Josephine Wu, DDS**, Assistant Director, Molecular Pathology Laboratory, Department of Pathology, Mount Sinai School of Medicine, Consulting Staff, Division of Oral and Maxillofacial Pathology, Department of Dental Medicine, Long Island Jewish Medical Center

Updated: Oct 28, 2008

Introduction

Background

Necrotizing sialometaplasia (NS) is a nonneoplastic inflammatory condition of the salivary glands. In 1973, Abrams et al first reported this condition.¹ The clinical and histopathologic features of necrotizing sialometaplasia often simulate those of malignancies such as squamous cell carcinoma or salivary gland malignancy.² All subsequent reports of necrotizing sialometaplasia stress the importance of correct diagnosis. Familiarity with necrotizing sialometaplasia and correct diagnosis are paramount in avoiding misdiagnosis and inappropriate treatment. Ischemia of salivary gland tissue leading to infarction (trauma) is the most likely cause.

A related eMedicine article that may be of interest is Cancers of the Oral Mucosa.

Pathophysiology

Necrotizing sialometaplasia was first reported to involve the minor salivary glands of the oral cavity, particularly those of the palate. Seventy-five percent of all cases occur on the posterior palate.³ Most are unilateral, with one third occurring in a bilateral or midpalatal location. Reports of this entity in the minor glands of the retromolar pad area, buccal mucosa, tongue, incisive canal, and labial mucosa followed. In addition, necrotizing sialometaplasia is recognized in the parotid and submandibular salivary glands,⁴ minor mucous glands in the lung,⁵ nasal cavity,^{6,7} larynx,^{8,9} trachea,¹⁰ nasopharynx, and maxillary sinus.¹¹ Similar lesions are identified in the breast; the condition is referred to as posttraumatic lobular metaplasia of the breast.¹²

Frequency

United States

Mesa and colleagues reported an incidence of 0.03% based on findings in 10,000 oral biopsy specimens.¹³ However, they state that this percentage does not account for cases of necrotizing sialometaplasia that heal spontaneously without biopsy.

International

Necrotizing sialometaplasia is reported worldwide. Isolated cases and reviews from Europe, North America, South America, and Asia are reported in the literature.

Mortality/Morbidity

The lesions of necrotizing sialometaplasia often are painless; less frequently, they cause pain and numbness. The clinical appearance that suggests cancer is the significant feature of this lesion. The clinical pictures show a patient with a lesion thought to be cancer who underwent biopsy and was monitored for 9 weeks. Over that time, regression of the lesion can be seen (see Media Files 1-4).

Race

- Brannon and colleagues¹⁴ reported that cases of necrotizing sialometaplasia in whites outnumbered cases in blacks by a ratio of 4.9:1.
- Given the ratio of whites to blacks in the United States, a significant racial predilection does not appear to exist.

Sex

- The male-to-female ratio is approximately 2:1.

Age

- The average age of patients with necrotizing sialometaplasia in the Armed Forces Institute of Pathology (AFIP) registry is 47.9 years, with a range of 17-80 years.
- The average age is 43.1 years for female patients and 50.3 years for male patients.
- A case of necrotizing sialometaplasia in an 18-month-old infant is reported.

Clinical

History

- Most cases of necrotizing sialometaplasia appear to arise spontaneously, whereas others are associated with a history of trauma, vomiting,^{15,16} radiation therapy, or surgery.¹⁵
- An association with neoplasia, such as parotid tumors, false vocal cord squamous cell carcinoma, and maxillary sinus carcinoma, is also reported.
- Cases associated with inflammatory conditions such as relapsing polychondritis and acute and chronic sinusitis have been noted to occur in the subglottic and sinus regions, respectively.

Physical

- Necrotizing sialometaplasia manifests as a swelling with or without ulceration in anatomic sites that have mucous or serous glandular tissue.
- The typical clinical presentation of necrotizing sialometaplasia is that of a crateriform ulcer of the palate that simulates a malignant process. These ulcerated lesions are 1-3 cm and are usually unilateral, but bilateral synchronous lesions and metachronous lesions can occur.^{17,18}
- Some lesions of necrotizing sialometaplasia may present as a submucosal swelling, without ulceration of the overlying mucosa. An intact surface mucosa may be noted in an evolving lesion at the time of diagnosis, although most cases are accompanied by mucosal ulceration.
- Erosion of the palatal bone may occur in either ulcerated or nonulcerated lesions.
- Examination of a biopsy specimen is usually required to establish the correct diagnosis and to exclude a malignant or infectious process or an inflammatory condition such as Wegener granulomatosis.
- Extranodal lymphoma also may be considered in the clinical differential diagnosis of a palatal swelling or ulceration.

Causes

- In most cases of necrotizing sialometaplasia, the etiology is believed to be related to vascular ischemia.
- Cases are reported in which vascular compression is caused by a necrotic myocutaneous reconstruction flap, embolization from carotid endarterectomy, sickle cell anemia,¹⁹ Buerger disease,²⁰ or Raynaud phenomenon.²⁰
- The association of adjacent neoplasia that results in ischemic necrosis of the glandular elements and the histologic features of necrotizing sialometaplasia supports this pathogenic mechanism.
- In an experimental study in a rat model, local anesthetic injections induced necrotizing sialometaplasia.²¹
- Tobacco use is suggested as a possible etiologic risk factor for necrotizing sialometaplasia.

Differential Diagnoses

Aphthous Stomatitis
Behcet Disease
Squamous Cell Carcinoma
Syphilis
Wegener Granulomatosis

Other Problems to Be Considered

Malignant salivary gland neoplasia
Benign salivary gland neoplasia
Lymphoma
Deep fungal Infections
Tuberculosis
Abscess
Oral lymphomatoid papulosis
Mucoepidermoid carcinoma
Subacute necrotizing sialadenitis

Workup

Imaging Studies

- A definitive tissue diagnosis of necrotizing sialometaplasia should exclude the need for radiographic imaging.
- If erosion of the palatal bone occurs with or without perforation, radiologic examination may be performed.

Procedures

- Incisional biopsy is necessary to establish the diagnosis of necrotizing sialometaplasia (NS).
 - An inadequate biopsy specimen may lead to the misdiagnosis of squamous cell carcinoma or mucoepidermoid carcinoma.
 - Findings in a superficial or limited biopsy specimen may be misinterpreted as a nonspecific ulcer or pseudoepitheliomatous hyperplasia of the surface mucosa.

Histologic Findings

The microscopic features of necrotizing sialometaplasia include coagulative necrosis of glandular acini and squamous metaplasia of its ducts. Mucin pooling is present, and an associated inflammatory infiltrate consists of macrophages; neutrophils; and, less commonly, lymphocytes, plasma cells, and eosinophils.

Pseudoepitheliomatous hyperplasia of the overlying mucosa can also be present, but the cytologic features of the squamous component are usually bland. Occasionally, isolated mucous cells may be entrapped within the squamous islands; these cells should not be confused with those of mucoepidermoid carcinoma.

The microscopic differential diagnosis for necrotizing sialometaplasia includes mucoepidermoid carcinoma and squamous cell carcinoma. Some believe that subacute necrotizing sialadenitis is yet another entity that occurs within the spectrum of necrotizing sialometaplasia; it should be distinguished from necrotizing sialometaplasia.

Treatment

Medical Care

Necrotizing sialometaplasia (NS) resolves spontaneously. No treatment is necessary.

Surgical Care

Surgical care for necrotizing sialometaplasia consists of incisional biopsy for diagnostic purposes.

Follow-up

Further Outpatient Care

Periodic evaluation of the affected site is recommended until spontaneous resolution occurs.

Prognosis

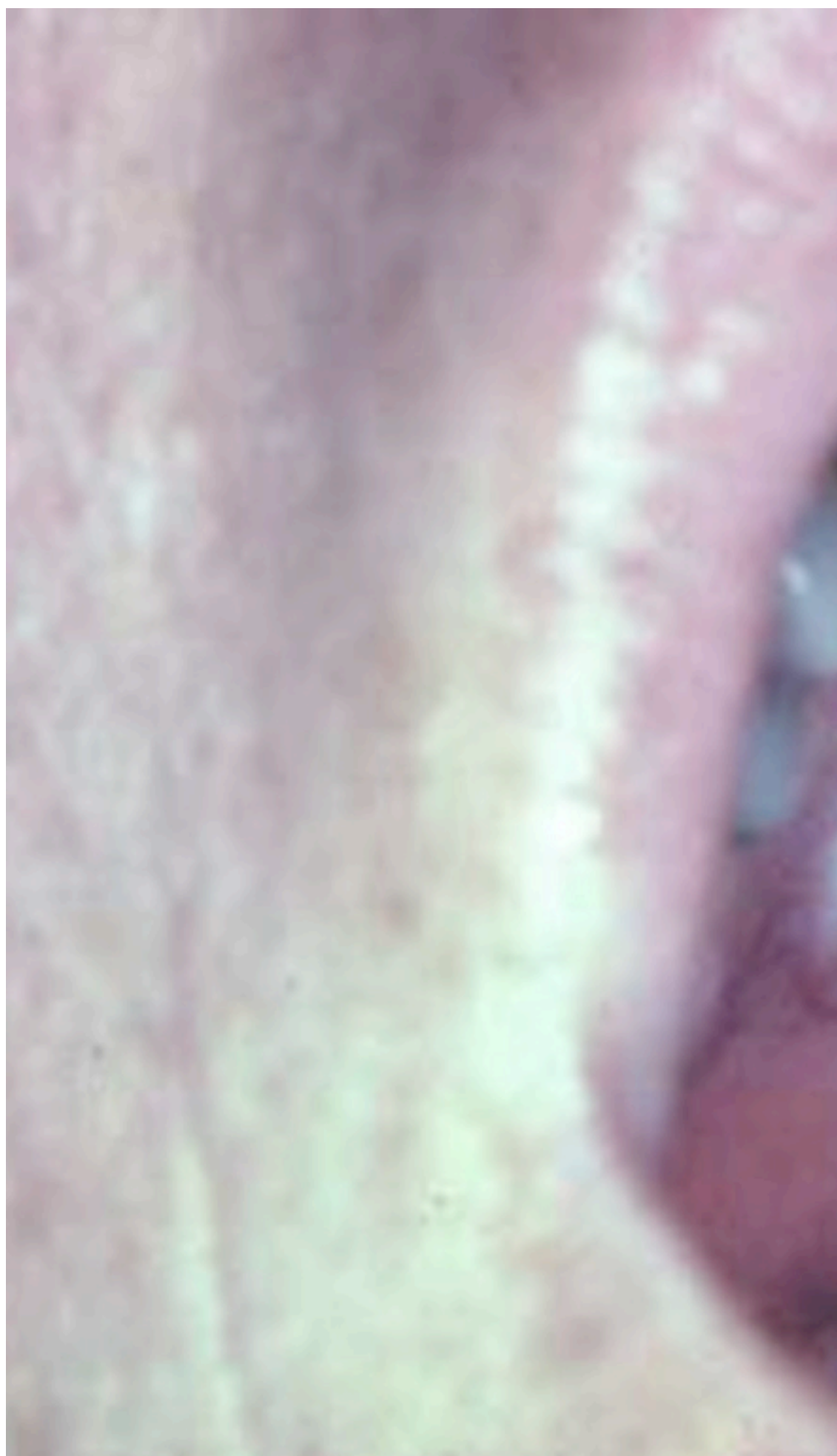
- The prognosis for necrotizing sialometaplasia (NS) is excellent.
- Spontaneous resolution usually occurs within weeks, although in the case presented, the lesion took more than 9 weeks to reach complete healing.
- The average healing time for necrotizing sialometaplasia of the minor salivary glands of the hard and soft palates is approximately 5 weeks.
- The size of the lesion and whether or not bony perforation has occurred are clinical parameters that may influence the healing time.

Miscellaneous

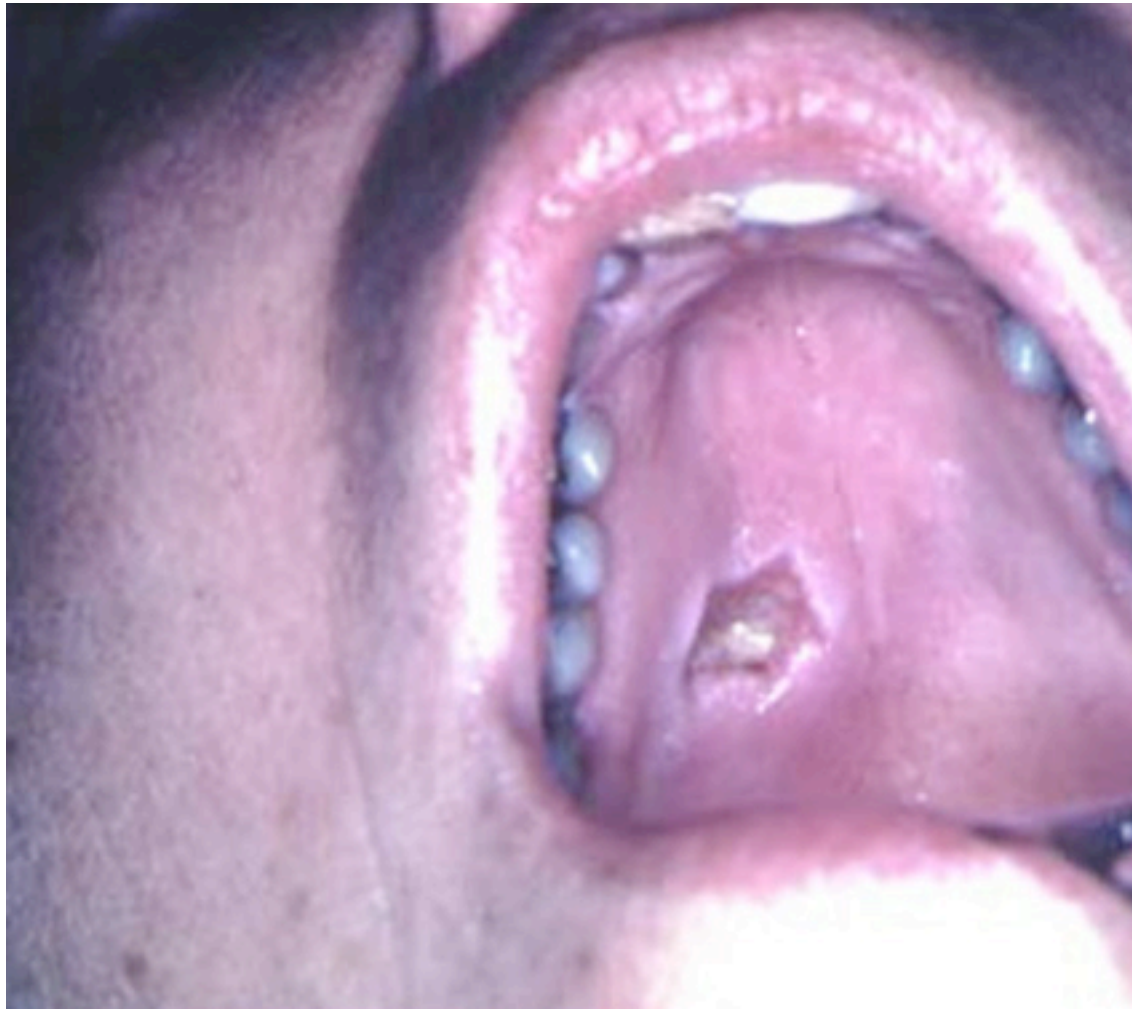Medicolegal Pitfalls

- Necrotizing sialometaplasia has been misdiagnosed as a mucoepidermoid carcinoma, squamous cell carcinoma, acinic cell carcinoma, verrucous carcinoma, ductal carcinoma, mucus-producing adenocarcinoma, or mixed tumor.
- In some cases, necrotizing sialometaplasia was misdiagnosed as pseudoepitheliomatous hyperplasia, a mucocele, or a pyogenic granuloma.
- Misdiagnosis can lead to significant adverse consequences for the patient.
- Necrotizing squamous metaplasia in herpetic tracheitis after prolonged intubation can simulate NS.²²
- The Medscape Medical Malpractice and Legal Issues Resource Center may be of interest.

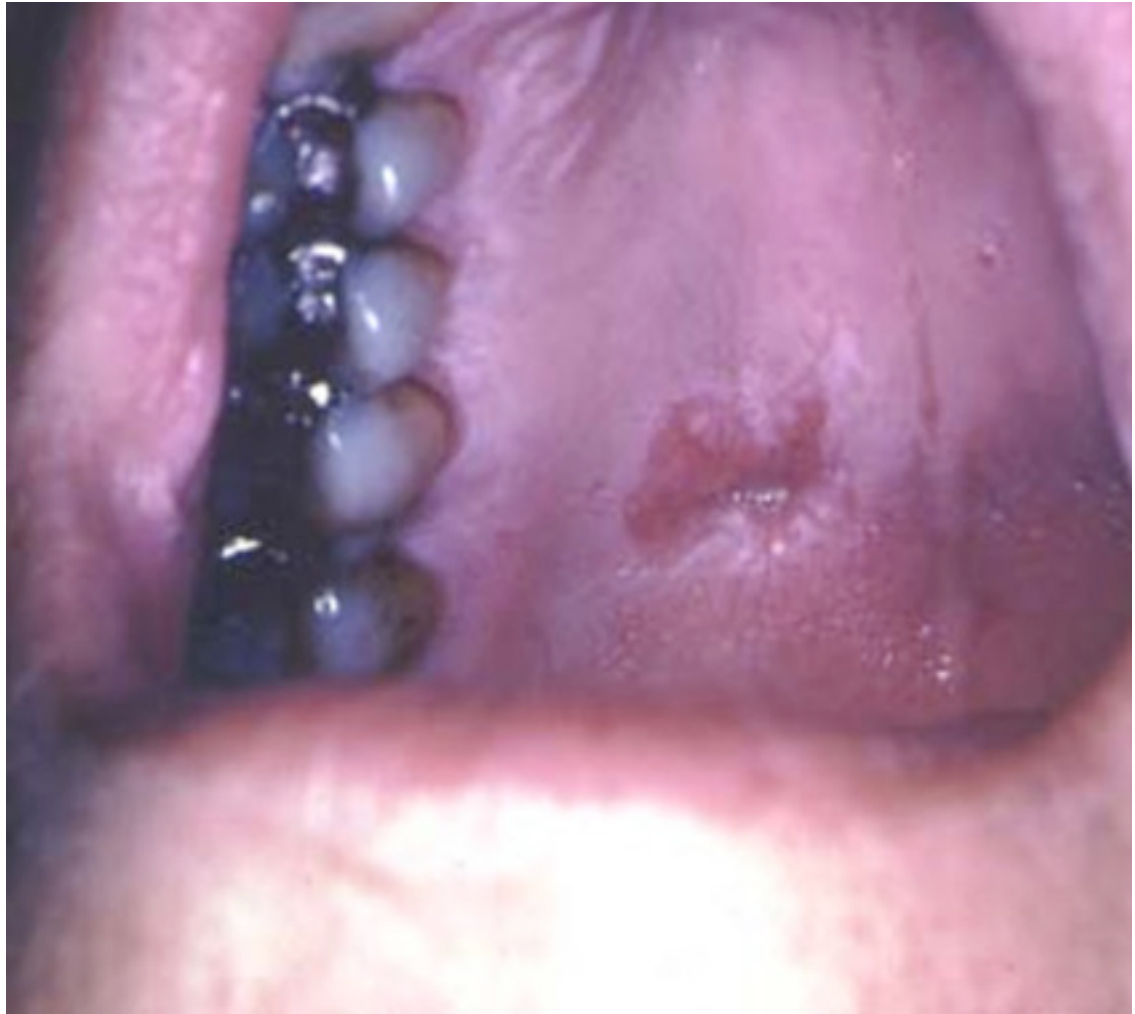Multimedia



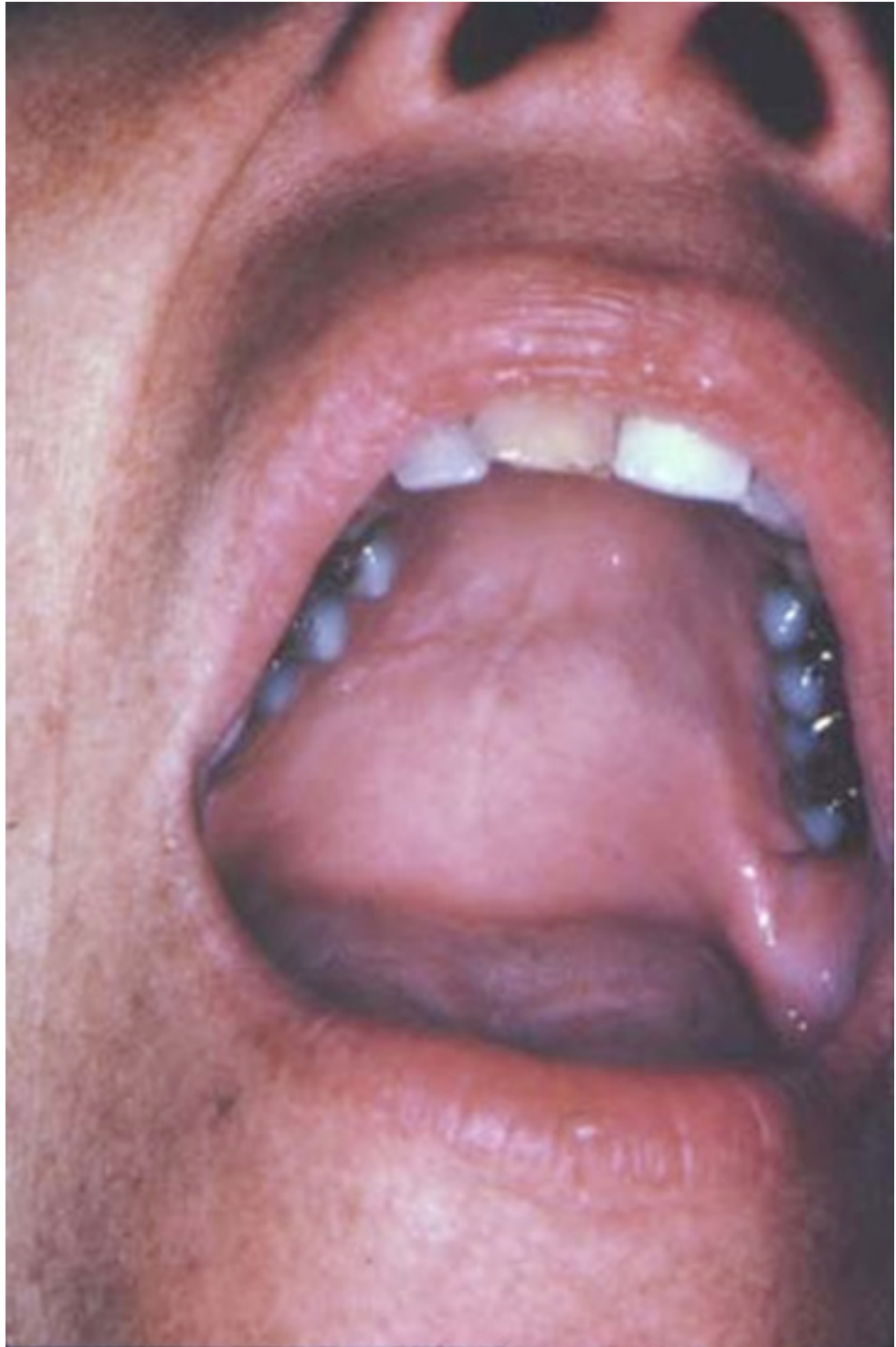Media file 1: Initial presentation (same patient as in Media Files 1-4).



Media file 2: Three weeks later after biopsy (same patient in Media Files 1, 3, and 4).



Media file 3: At 6 weeks (same patient as in Media Files 1, 2, and 4).



Media file 4: Nine weeks. Salivary gland infarction (same patient as in Media Files 1-3).

References

33. Abrams AM, Melrose RJ, Howell FV. Necrotizing sialometaplasia. A disease simulating malignancy. *Cancer*. Jul 1973;32(1):130-5. [[Medline](#)].

34. Franchi A, Gallo O, Santucci M. Pathologic quiz case 1. Necrotizing sialometaplasia obscuring recurrent well-differentiated squamous cell carcinoma of the maxillary sinus. *Arch Otolaryngol Head Neck Surg.* May 1995;121(5):584, 586. [\[Medline\]](#).
35. Schmidt-Westhausen A, Philippsen HP, Reichart PA. [Necrotizing sialometaplasia of the palate. Literature report of 3 new cases]. *Dtsch Z Mund Kiefer Gesichtschir.* Jan-Feb 1991;15(1):30-4. [\[Medline\]](#).
36. Batsakis JG, Manning JT. Necrotizing sialometaplasia of major salivary glands. *J Laryngol Otol.* Sep 1987;101(9):962-6. [\[Medline\]](#).
37. Zschoch H. [Mucus gland infarct with squamous epithelial metaplasia in the lung. A rare site of so-called necrotizing sialometaplasia]. *Pathologe.* Feb 1992;13(1):45-8. [\[Medline\]](#).
38. Abrams AM. Necrotizing sialometaplasia of the nasal cavity. *Otolaryngol Head Neck Surg.* Mar 1986;94(3):416. [\[Medline\]](#).
39. Chen KT. Necrotizing sialometaplasia of the nasal cavity. *Am J Otolaryngol.* Nov-Dec 1982;3(6):444-6. [\[Medline\]](#).
40. Walker GK, Fechner RE, Johns ME, Teja K. Necrotizing sialometaplasia of the larynx secondary to atheromatous embolization. *Am J Clin Pathol.* Feb 1982;77(2):221-3. [\[Medline\]](#).
41. Wenig BM. Necrotizing sialometaplasia of the larynx. A report of two cases and a review of the literature. *Am J Clin Pathol.* May 1995;103(5):609-13. [\[Medline\]](#).
42. Romagosa V, Bella MR, Truchero C, Moya J. Necrotizing sialometaplasia (adenometaplasia) of the trachea. *Histopathology.* Sep 1992;21(3):280-2. [\[Medline\]](#).
43. Bell GW, Loukota RA. Necrotizing sialometaplasia coincident with ipsilateral infarcted antral polyps. *Br J Oral Maxillofac Surg.* Feb 1996;34(1):129-31. [\[Medline\]](#).
44. Hurt MA, Diaz-Arias AA, Rosenholtz MJ, Havey AD, Stephenson HE Jr. Posttraumatic lobular squamous metaplasia of breast. An unusual pseudocarcinomatous metaplasia resembling squamous (necrotizing) sialometaplasia of the salivary gland. *Mod Pathol.* Sep 1988;1(5):385-90. [\[Medline\]](#).
45. Mesa ML, Gertler RS, Schneider LC. Necrotizing sialometaplasia: frequency of histologic misdiagnosis. *Oral Surg Oral Med Oral Pathol.* Jan 1984;57(1):71-3. [\[Medline\]](#).
46. Brannon RB, Fowler CB, Hartman KS. Necrotizing sialometaplasia. A clinicopathologic study of sixty-nine cases and review of the literature. *Oral Surg Oral Med Oral Pathol.* Sep 1991;72(3):317-25. [\[Medline\]](#).
47. Aframian D, Milhem I I, Kirsch G, Markitziu A. Necrotizing Sialometaplasia after Silastic Ring Vertical Gastroplasty: Case Report and Review of Literature. *Obes Surg.* May 1995;5(2):179-182. [\[Medline\]](#).
48. Schöning H, Emshoff R, Kreczy A. Necrotizing sialometaplasia in two patients with bulimia and chronic vomiting. *Int J Oral Maxillofac Surg.* Dec 1998;27(6):463-5. [\[Medline\]](#).
49. Rossie KM, Allen CM, Burns RA. Necrotizing sialometaplasia: a case with metachronous lesions. *J Oral Maxillofac Surg.* Dec 1986;44(12):1006-8. [\[Medline\]](#).
50. Stafford RF, Sonis ST, Shklar G. Bilateral necrotizing sialometaplasia: a case report. *J Oral Med.* Apr-Jun 1981;36(2):28-30. [\[Medline\]](#).
51. Mandel L, Kaynar A, DeChiara S. Necrotizing sialometaplasia in a patient with sickle-cell anemia. *J Oral Maxillofac Surg.* Jul 1991;49(7):757-9. [\[Medline\]](#).
52. Rye LA, Calhoun NR, Redman RS. Necrotizing sialometaplasia in a patient with Buerger's disease and Raynaud's phenomenon. *Oral Surg Oral Med Oral Pathol.* Mar 1980;49(3):233-6. [\[Medline\]](#).
53. Shigematsu H, Shigematsu Y, Noguchi Y, Fujita K. Experimental study on necrotizing sialometaplasia of the palate in rats. Role of local anesthetic injections. *Int J Oral Maxillofac Surg.* Jun 1996;25(3):239-41. [\[Medline\]](#).
54. Ben-Izhak O, Ben-Arieh Y. Necrotizing squamous metaplasia in herpetic tracheitis following prolonged intubation: a lesion similar to necrotizing sialometaplasia. *Histopathology.* Mar 1993;22(3):265-9. [\[Medline\]](#).
55. Anneroth G, Hansen LS. Necrotizing sialometaplasia. The relationship of its pathogenesis to its clinical characteristics. *Int J Oral Surg.* Oct 1982;11(5):283-91. [\[Medline\]](#).
56. Brooks DG, Hottinger HA, Dunstan RW. Canine necrotizing sialometaplasia: a case report and review of the literature. *J Am Anim Hosp Assoc.* Jan-Feb 1995;31(1):21-5. [\[Medline\]](#).
57. Forney SK, Foley JM, Sugg WE Jr, Oatis GW Jr. Necrotizing sialometaplasia of the mandible. *Oral Surg Oral Med Oral Pathol.* May 1977;43(5):720-6. [\[Medline\]](#).
58. Fowler CB, Brannon RB. Subacute necrotizing sialadenitis: report of 7 cases and a review of the literature. *Oral Surg Oral Med Oral Pathol Oral Radiol Endod.* May 2000;89(5):600-9. [\[Medline\]](#).

59. Gnepp DR. Warthin tumor exhibiting sebaceous differentiation and necrotizing sialometaplasia. *Virchows Arch A Pathol Anat Histol.* 1981;391(3):267-73. [\[Medline\]](#).
60. Granich MS, Pilch BZ. Necrotizing sialometaplasia in the setting of acute and chronic sinusitis. *Laryngoscope.* Sep 1981;91(9 Pt 1):1532-5. [\[Medline\]](#).
61. Granick MS, Solomon MP, Benedetto AV, Hannegan MW, Sohn M. Necrotizing sialometaplasia masquerading as residual cancer of the lip. *Ann Plast Surg.* Aug 1988;21(2):152-4. [\[Medline\]](#).
62. Imbery TA, Edwards PA. Necrotizing sialometaplasia: literature review and case reports. *J Am Dent Assoc.* Jul 1996;127(7):1087-92. [\[Medline\]](#).
63. Jankittivong A, Sookasam M, Philipsen HP. Necrotizing sialometaplasia: review of 127 cases. *J Dent Assoc Thai.* Jan-Feb 1989;39(1):11-6. [\[Medline\]](#).
64. Jensen JL. Idiopathic diseases. In: Ellis GL, Auclair PL, Gnepp DR, eds.