

## eMedicine Specialties > Dermatology > Diseases of the Oral Mucosa

# Oral Lymphangiomas

**Sean P Edwards, BSc, DDS, MD, FRCD(C)**, Assistant Professor, Chief of Pediatric Oral and Maxillofacial Surgery, Section of Oral and Maxillofacial Surgery, Department of Surgery, C S Mott Children's Hospital, University of Michigan Medical Center

**Joseph Helman, DMD**, Clinical Professor and Chair, Department of Oral and Maxillofacial Surgery, University of Michigan

Updated: Jun 16, 2009

## Introduction

### Background

Lymphangiomas and cystic hygromas are rare benign hamartomatous lesions of the lymphatic system. Determining the true incidence of these lesions is difficult because uniformity in classification and nomenclature is lacking. Moreover, lymphatic malformations are generally treated in tertiary and quaternary medical centers, distorting any view of their true incidence.

These lesions, more correctly referred to as lymphatic malformations, have a marked predilection for the head and neck, with as many as 75% presenting therein. No clear sex predilection is demonstrated, and whites appear to be affected more often than people of other races.

Of lymphatic malformations, 50% are present at birth, and 90% are diagnosed by the time the individual is aged 2 years. However, the time of diagnosis can range from 19 weeks' gestation to the individual's second decade of life.

Of lymphatic malformations in the oral cavity, 40-50% involve the tongue, which is the preferred site of intraoral involvement. The buccal mucosa is the second most common. These distinctions can be somewhat artificial because lesions that involve the oral cavity may extend from the orbits to the upper mediastinum and axillae.

Lymphatic malformations are typically classified as simple microcystic, simple macrocystic, or mixed microcystic and macrocystic lesions, according to their predominant histologic features.<sup>1</sup>

### Pathophysiology

Although no clear consensus on the mechanism for lesion development exists, the lesions likely develop as a result of aberrant sequestration of portions of the primitive embryonic anlagen. The sequestered areas never achieve efficient anastomoses with the larger lymph channels and, as a result, they consist of little more than functionally blocked lymphatic tracts. This blockage may result in increased hydrostatic pressure with subsequent expansion of the lesion until a pressure equilibrium is achieved with the surrounding tissues. The importance of the surrounding tissues in determining the nature of the lesion is evident, as microcystic lesions are more common in the tongue, whereas macrocystic lesions predominate in the relatively compliant tissues of the neck.

At the molecular level, some have hypothesized overexpression of growth factors or their associated receptors essential to lymphatic development. Two examples would be vascular endothelial growth factor types 3 and C.

A neoplasm is classically defined as an abnormal mass of tissue. Its growth exceeds and is uncoordinated with that of healthy tissues and persists in an excessive manner after the inciting stimuli is removed. In contrast, lymphatic malformations and/or lymphangiomas tend to grow commensurately with the child's growth and rarely regress spontaneously. Rapid enlargement of the lesions (out of proportion with the surrounding tissues) is observed only in conjunction with infections of the upper respiratory tract or the lesion itself or with trauma and hemorrhage into the malformation. In addition, the lesions have a typical endothelial cell cycle.

For these reasons, lymphangiomas are considered to be malformations rather than neoplasms. In a teleologic sense, this determination remains rather unsatisfying because the predisposing event (ie, the sequestration of embryonic anlagen) occurs long before these lesions develop. As previously stated, only 50% of the lesions are diagnosed at birth, and a few reports of lesions developing in early adulthood exist.

Moreover, at prenatal ultrasonography, fetal lymphatic malformations are observed to develop and occasionally resolve in utero. Some unrecognized event must be superimposed on these earlier events resulting in the development of a clinically apparent lesion. These events are apparently reversible because the lesions occasionally salvato da Windows Internet Explorer 8> Subject: Oral Lymphangiomas: [Print] - eMedicine Dermatology Date: Fri, 4 Sep 2009 01:45:13 +0200 MIME-Version: 1.0 Content-Type: multipart/related; type="text/html"; boundary="-----\_NextPart\_000\_00CE\_01CA2D01.58944650" X-MimeOLE: Produced By Microsoft MimeOLE V6.00.2900.5579 This is a multi-part message in MIME format. -----=\_NextPart\_000\_00CE\_01CA2D01.58944650 Content-Type: text/html; charset="Windows-1252" Content-Transfer-Encoding: quoted-printable Content-Location: <http://emedicine.medscape.com/article/1076948-print>



[emedicine.medscape.com](http://emedicine.medscape.com)

## eMedicine Specialties > Dermatology > Diseases of the Oral Mucosa

# Oral Lymphangiomas

**Sean P Edwards, BSc, DDS, MD, FRCD(C)**, Assistant Professor, Chief of Pediatric Oral and Maxillofacial Surgery, Section of Oral and Maxillofacial Surgery, Department of Surgery, C S Mott Children's Hospital, University of Michigan Medical Center

**Joseph Helman, DMD**, Clinical Professor and Chair, Department of Oral and Maxillofacial Surgery, University of Michigan

Updated: Jun 16, 2009

## Introduction

### Background

Lymphangiomas and cystic hygromas are rare benign hamartomatous lesions of the lymphatic system. Determining the true incidence of these lesions is difficult because uniformity in classification and nomenclature is lacking. Moreover, lymphatic malformations are generally treated in tertiary and quaternary medical centers, distorting any view of their true incidence.

These lesions, more correctly referred to as lymphatic malformations, have a marked predilection for the head and neck, with as many as 75% presenting therein. No clear sex predilection is demonstrated, and whites appear to be affected more often than people of other races.

Of lymphatic malformations, 50% are present at birth, and 90% are diagnosed by the time the individual is aged 2 years. However, the time of diagnosis can range from 19 weeks' gestation to the individual's second decade of life.

Of lymphatic malformations in the oral cavity, 40-50% involve the tongue, which is the preferred site of intraoral involvement. The buccal mucosa is the second most common. These distinctions can be somewhat artificial because lesions that involve the oral cavity may extend from the orbits to the upper mediastinum and axillae.

Lymphatic malformations are typically classified as simple microcystic, simple macrocystic, or mixed microcystic and macrocystic lesions, according to their predominant histologic features.<sup>1</sup>

## Pathophysiology

Although no clear consensus on the mechanism for lesion development exists, the lesions likely develop as a result of aberrant sequestration of portions of the primitive embryonic anlagen. The sequestered areas never achieve efficient anastomoses with the larger lymph channels and, as a result, they consist of little more than functionally blocked lymphatic tracts. This blockage may result in increased hydrostatic pressure with subsequent expansion of the lesion until a pressure equilibrium is achieved with the surrounding tissues. The importance of the surrounding tissues in determining the nature of the lesion is evident, as microcystic lesions are more common in the tongue, whereas macrocystic lesions predominate in the relatively compliant tissues of the neck.

At the molecular level, some have hypothesized overexpression of growth factors or their associated receptors essential to lymphatic development. Two examples would be vascular endothelial growth factor types 3 and C.

A neoplasm is classically defined as an abnormal mass of tissue. Its growth exceeds and is uncoordinated with that of healthy tissues and persists in an excessive manner after the inciting stimuli is removed. In contrast, lymphatic malformations and/or lymphangiomas tend to grow commensurately with the child's growth and rarely regress spontaneously. Rapid enlargement of the lesions (out of proportion with the surrounding tissues) is observed only in conjunction with infections of the upper respiratory tract or the lesion itself or with trauma and hemorrhage into the malformation. In addition, the lesions have a typical endothelial cell cycle.

For these reasons, lymphangiomas are considered to be malformations rather than neoplasms. In a teleologic sense, this determination remains rather unsatisfying because the predisposing event (ie, the sequestration of embryonic anlagen) occurs long before these lesions develop. As previously stated, only 50% of the lesions are diagnosed at birth, and a few reports of lesions developing in early adulthood exist.

Moreover, at prenatal ultrasonography, fetal lymphatic malformations are observed to develop and occasionally resolve in utero. Some unrecognized event must be superimposed on these earlier events resulting in the development of a clinically apparent lesion. These events are apparently reversible because the lesions occasionally spontaneously regress in fetuses and children. The inciting event must then be occurring during the maturation of the formed lymphatic systems.

## Frequency

### International

Determining the true incidence of these lesions is difficult because uniformity in classification and nomenclature is lacking. Moreover, lymphatic malformations are generally treated in tertiary and quaternary medical centers.

## Mortality/Morbidity

The oral cavity is a highly specialized structure that is important for speech, deglutition, mastication, and airway maintenance. The functional and anatomic aberrations that result from an oral lymphatic malformation may negatively affect each of these specialized functions. In addition, the aesthetic consequences of an oral lymphatic malformation can be severe and significantly impair a child's psychosocial development. See Complications.

- Infection-related morbidity: Approximately 70-80% of patients with lymphatic malformations experience infections, often associated with significant increases in the size of lesions.<sup>2</sup> Management of these episodes requires aggressive, early institution of broad-spectrum antibiotic therapy. This typically consists of admission to hospital for a course of parenteral antibiotics followed by a prolonged course of oral antibiotics. Susceptibility to infection of these lesions probably pertains to the structural abnormalities of the tissues and the lymphatic system and its important role in mounting an immune response. Further, lymphocytopenias have been documented in this population, although they have yet to be definitely correlated to an increased risk of infection.<sup>3</sup>
- Airway-related morbidity: Rapid enlargement of the lesion either as a result of intralesional hemorrhage or infection may lead to airway obstruction. The clinician must be very vigilant in this regard. As a result of these concerns, approximately 50% of children with such lesions require tracheostomy.

## Race

- Whites appear to be affected more than people of other races.
- One exceptional form of lymphatic malformation occurs on the alveolar ridge in approximately 4% of black neonates. This lesion is generally bilateral and smaller than 1 cm. A male-to-female ratio of 2:1 is observed in this particular form, which apparently resolves spontaneously and does not require treatment.

## Sex

- No clear sex predilection is demonstrated.

## Age

- Of lymphatic malformations, 50% are present at birth, and 90% are diagnosed by the time the individual is aged 2 years. However, the time of diagnosis can range from 19 weeks' gestation to the individual's second decade of life.<sup>4</sup>

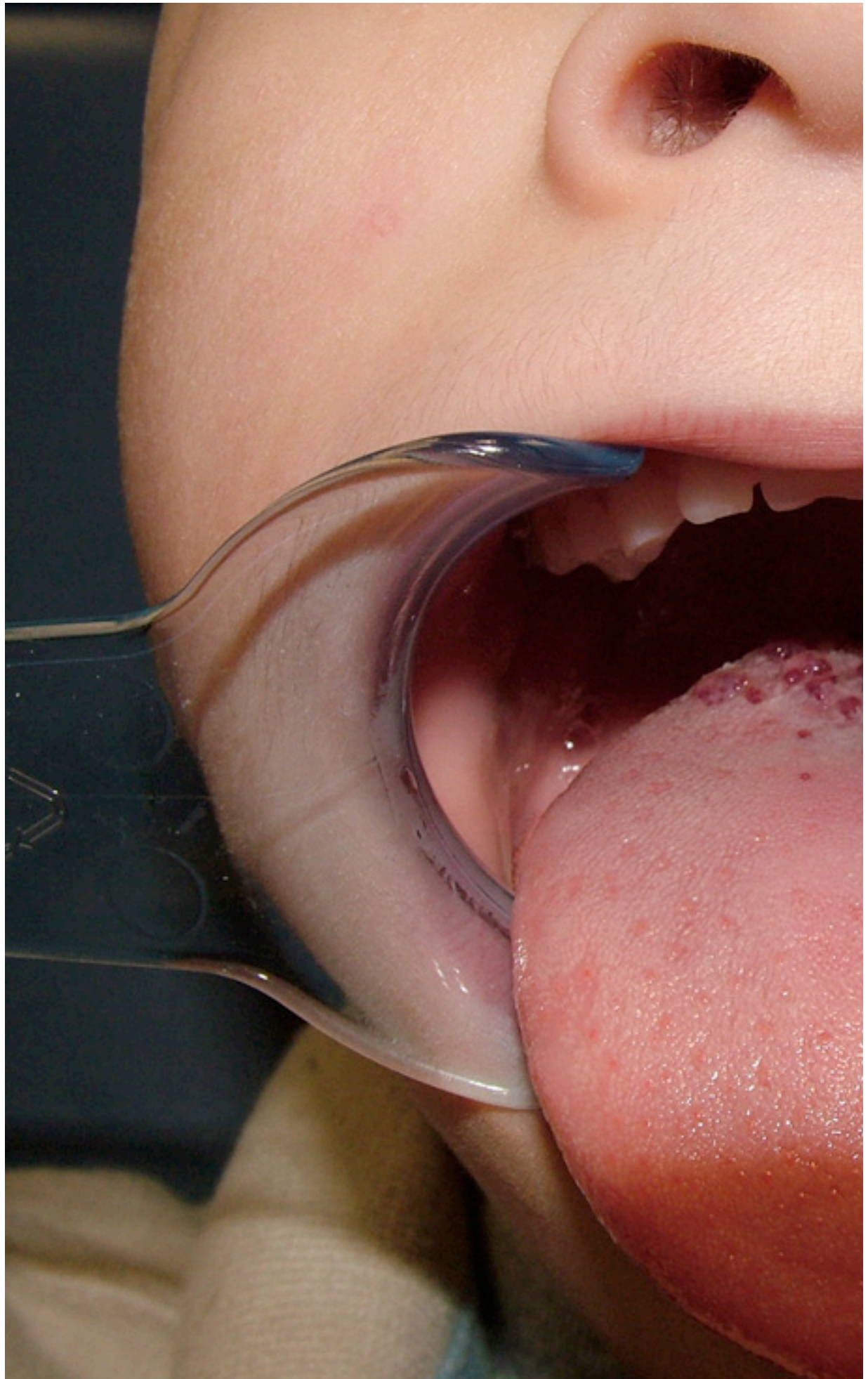
## Clinical

### History

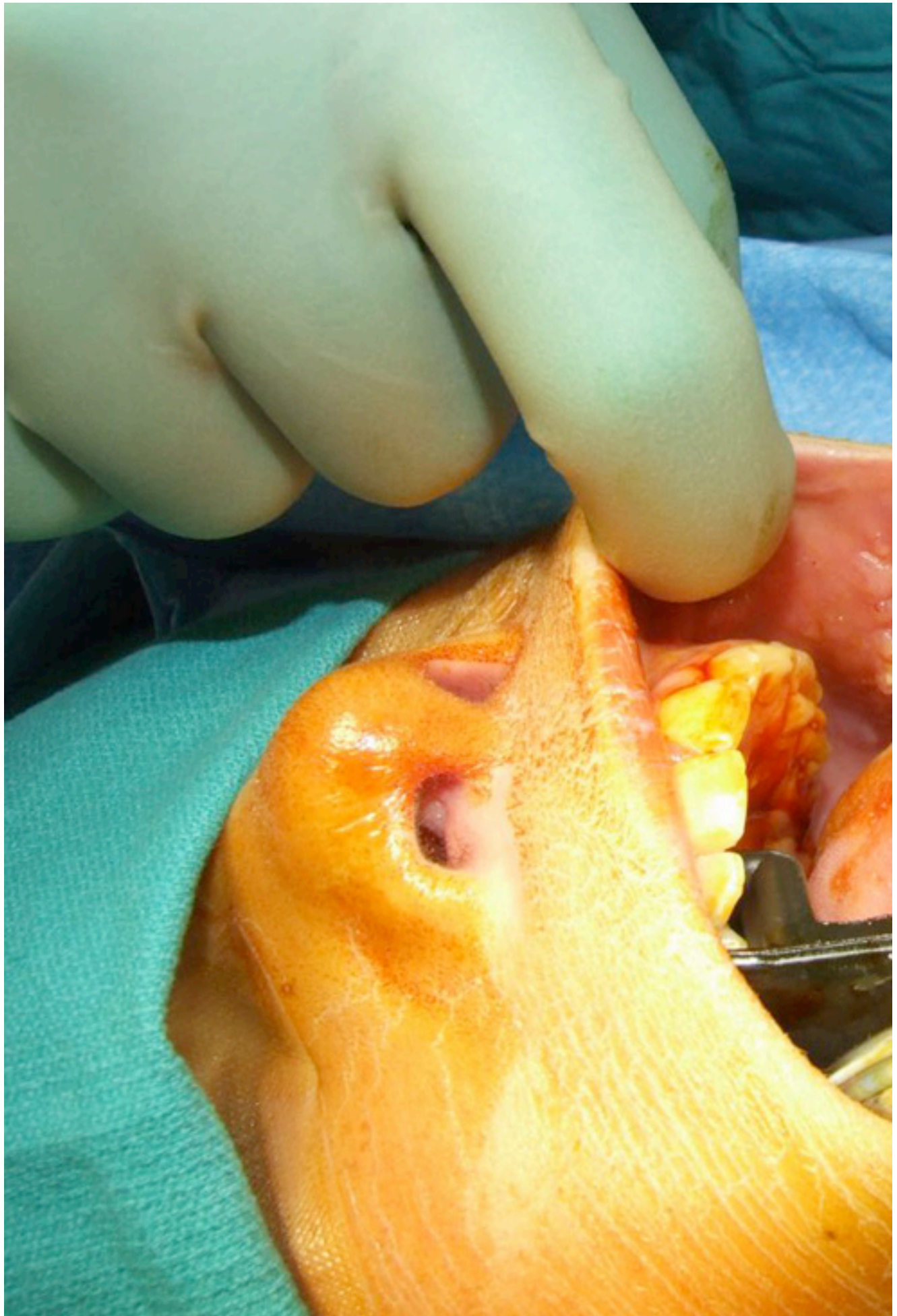- Although most lesions appear in the individual's first 2 years of life, lesions occasionally appear in early adulthood.
- Typical histories include annoying and repetitive surface bleeding, paroxysms of lesion expansion, usually in association with upper respiratory tract infections, intralesional hemorrhage, or repeated infections.

### Physical

- Superficial lymphatic malformations have a pebbly surface and are clear or bluish. The bluish color may be caused by either a venous component or an intralesional hemorrhage.

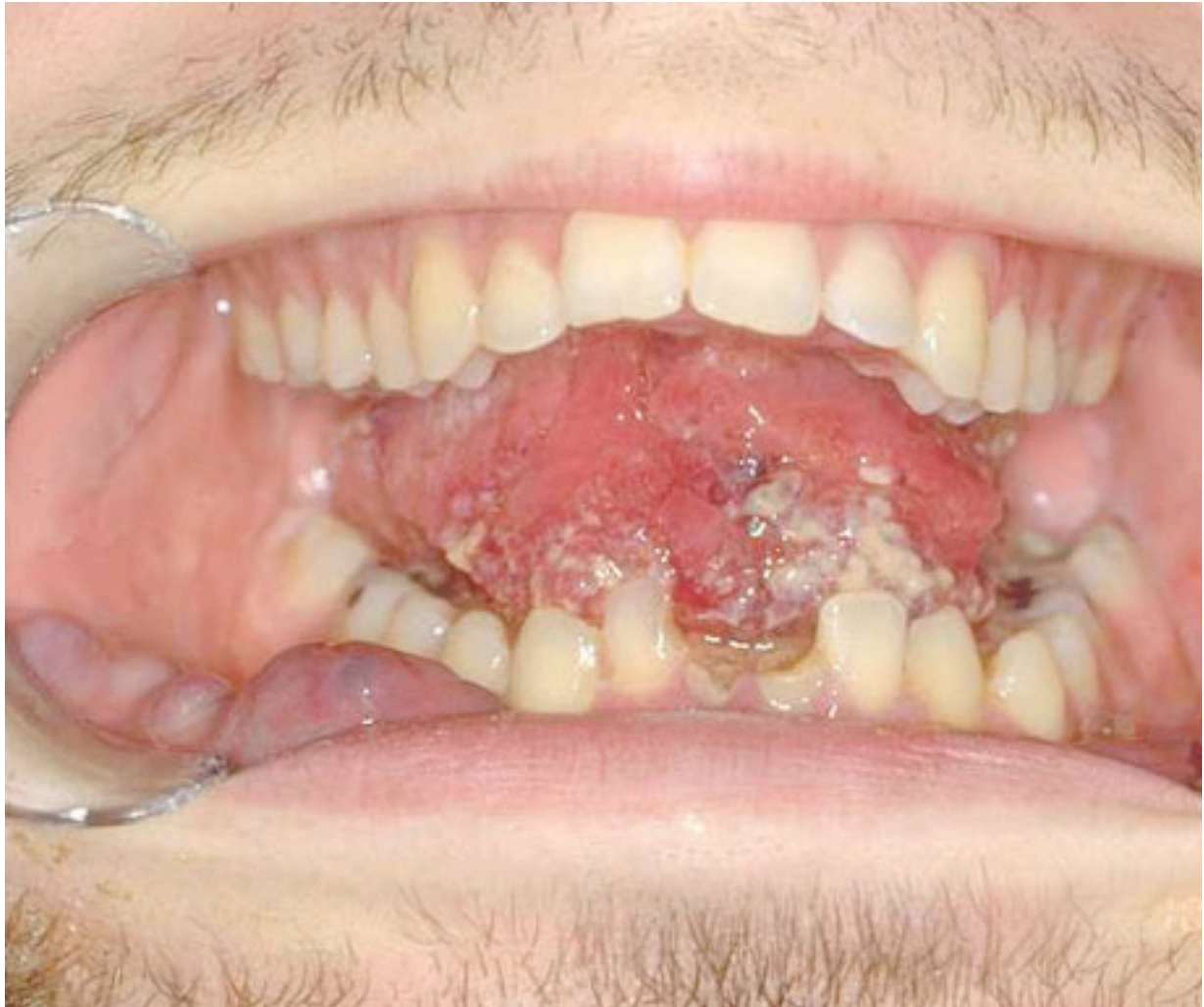

**Superficial lymphatic malformation.**



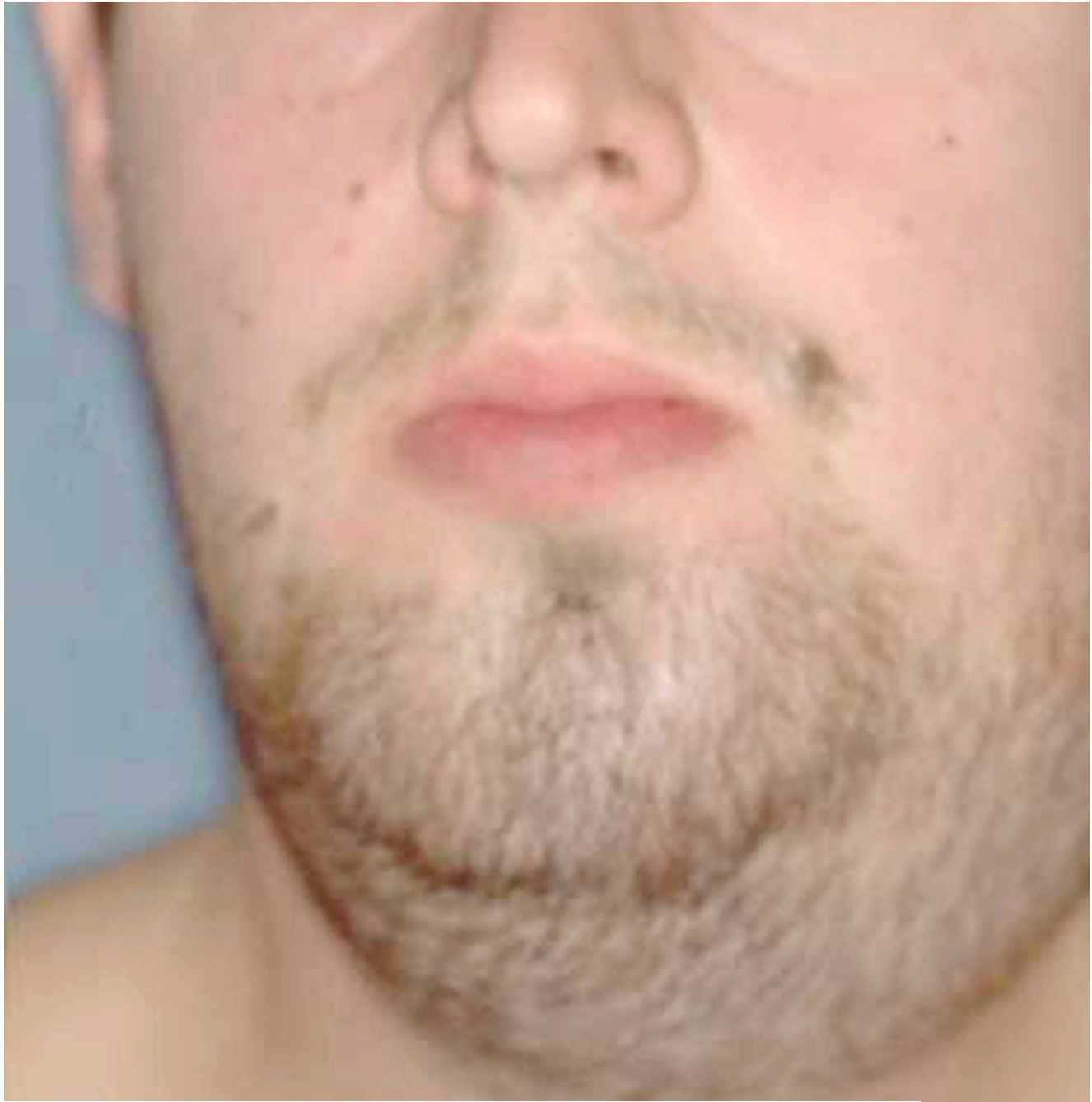## Superficial lymphatic malformation.

- Deeper lesions may have a superficial component. When a superficial component is absent, deeper lesions usually appear as soft, ill-defined masses that markedly distort the local anatomy.

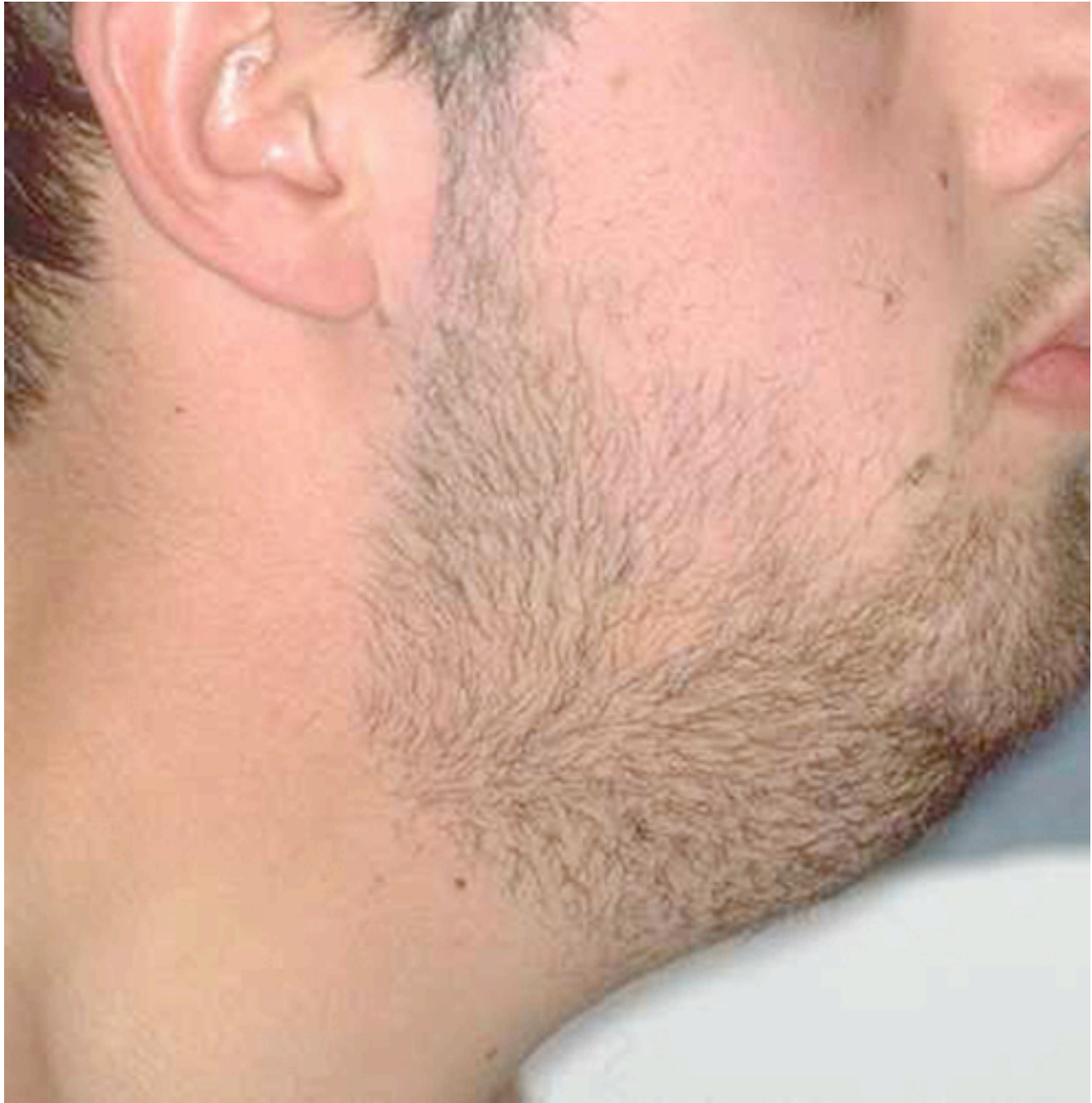

**Marked lingual enlargement caused by lymphatic malformation. Note the pebbly surface in areas not covered by materia alba. Also note the ecchymotic lesions protruding from the buccal mucosa in the mandibular vestibules.**





**Note the significant left buccal and submandibular swelling.**



**Profile view of a young adult with oral lymphangioma (same patient as in Media File 2).**

- Macrocystic lesions may be fluctuant and readily transilluminating.

## **Causes**

- Although no clear consensus on the mechanism for lesion development exists, the lesions likely develop as a result of aberrant sequestration of portions of these primitive embryonic anlagen. See Pathophysiology.

# Differential Diagnoses

Branchial Cleft Cyst  
Cellulitis  
Cheilitis Granulomatosa (Miescher-Melkersson-Rosenthal Syndrome)  
Dermoid Cyst

Infantile Hemangioma  
Lymphangioma  
Mucocele and Ranula  
Oral Hemangiomas

## Other Problems to Be Considered

Thyroglossal duct cyst

## Workup

### Imaging Studies

Approximately 40% of lesions are diagnosed on the basis of their clinical appearance alone; however, this observation does not obviate further imaging. Imaging plays several roles in the evaluation and treatment of oral lymphatic malformations. Imaging helps in determining the extent of the lesion and its proximity to vital structures, in determining whether the lesion contains a vascular component, and is used to assess recurrence in treated lesions.

- Ultrasonography
  - Prenatal ultrasonography can be used to identify fetal cystic hygromas. A diagnosis of fetal cystic hygroma has important ramifications for the fetus because this lesion is often associated with major chromosomal abnormalities. However, caution is warranted with such a diagnosis because these lesions are known to regress in utero. In addition, the prenatal diagnosis of fetal cystic hygroma has an error rate as high as 70%, depending on the time of diagnosis.
  - Ultrasonography may be an invaluable tool for monitoring a lesion for regression or recurrence. Lesions will appear cystic on ultrasound, with little evidence of flow upon Doppler interrogation.
- MRI<sup>s</sup>
  - Contrast-enhanced MRI is the most useful imaging modality for the assessment of lymphatic malformations.
  - The superior soft-tissue definition is critical in planning surgery and determining the extent of the lesion.
  - MRI is particularly important in distinguishing vascular malformations or mixed lesions from lymphatic malformations. Both vascular and lymphatic variants have a low signal intensity on T1-weighted images and high signal intensity on T2-weighted images. However, in contrast to vascular malformations, lymphatic variants fail to enhance after the administration of contrast material.
  - Fetal MRI is an excellent diagnostic tool for further evaluation of oral and anterior cervical lesions detected on prenatal ultrasound. It can be invaluable in determining the potential for airway obstruction and the need for ex utero intrapartum treatment (EXIT procedure) at delivery.
- CT scanning
  - CT scans are superior to MRIs in delineating bony deformation.
  - CT scans are superior to other modalities in detecting phleboliths, which were once considered pathognomonic of venous malformations. Phleboliths observed in lymphatic malformations are most likely caused by a previous intralesional hemorrhage.
  - Three-dimensional CT scans may be obtained to permit the fabrication of stereolithographic models with which to plan orthognathic surgical correction of the maxillofacial skeletal deformity at maturity.
- Plain radiography: Posteroanterior and lateral cephalometric radiographs are invaluable in diagnosing maxillofacial skeletal deformities secondary to lymphatic malformations.

### Histologic Findings

Superficial lesions consist of dilated lymph vessels lined by flat endothelial cells in a discontinuous layer immediately subjacent to the oral epithelium. These lesions often replace the dermal papillae, but they can also extend into the deeper connective tissue.

Deeper lesions consist of irregular, dilated, and interconnected lymphatic vessels, some of which reveal macroscopic cyst formation (eg, cystic hygroma, cystic lymphangioma, lymphangioma cystoides). The walls of the vessels variably contain smooth muscle bundles. Lymphoid aggregates and germinal centers can be observed in both the surrounding tissues and the walls of the lesion. Cystic spaces generally contain a lightly eosinophilic, proteinaceous fluid with scant lymphocytes.

In contrast to vascular malformations, electron microscopy and immunohistochemical techniques demonstrate irregular and fragmented basal lamina in the lymphatic malformations.

## Staging

- Lymphatic malformations in the oral cavity can be classified as superficial lesions and deep lesions on the basis of their histologic and clinical features.
  - Superficial lesions include lymphangioma simplex, lymphangioma circumscriptum, and capillary hemangioma.
  - Deep lesions are further divided into microcystic variants (eg, cavernous lymphangioma) and macrocystic variants (eg, lymphangioma cystoides, cystic lymphangioma, cystic hygroma).
- In the oral cavity, superficial and microcystic lesions are most common.
- Below the mandible and above the maxilla, macrocystic lesions predominate.
- Any lesion may comprise any or all of the histomorphologic variants.
- A staging system for cervical lymphatic malformations by de Serres is based on the extent of anatomical involvement. It has been validated in terms of its ability to predict the incidence of preoperative complications, postoperative complications, long-term morbidity, and risk of recurrence, which increase with the stage of the lesion. The system is perhaps better termed a classification because staging implies a progressive neoplastic behavior.
  - Stage/class I - Unilateral infrahyoid lesions
  - Stage/class II - Unilateral suprahyoid lesions
  - Stage/class III - Unilateral suprahyoid and infrahyoid lesions
  - Stage/class IV - Bilateral suprahyoid lesions
  - Stage/class V - Bilateral suprahyoid and infrahyoid lesions
  - Stage/class VI - Bilateral infrahyoid lesions

## Treatment

### Medical Care

No appropriate medical care is available for oral lymphatic malformations, other than observation in selected patients. For example, a child with a superficial lesion without untoward functional sequelae may be observed. In all patients, address the perioperative airway, speech, and nutritional concerns.

- Observation
  - Some authors advocate a period of watchful waiting in cases of asymptomatic lesions because a few reports show that the lesions regress spontaneously.
  - Other authors recommend excision as soon as the patient can safely tolerate a general anesthetic. These authors are concerned about the complications associated with untreated lesions and recognize the fact that repeated infections make future excision difficult.
- Radiation therapy
  - Radiation therapy is of only historical interest.
  - This treatment should not be used because of its poor effectiveness, its multiple complications, and the risk of postradiation malignancies.

### Surgical Care

Treatment of lymphatic malformations continues to evolve. Although surgical removal is overwhelmingly the most common modality used, sclerotherapy is being increasingly used to treat macrocystic lesions throughout the head and neck. Often the 2 modalities are combined for optimal outcomes. Determine the timing of intervention on a case-by-case basis. Lesions that impinge on the airway usually require the earliest intervention.

Isolated superficial malformations are often more of a nuisance than a debilitating condition. Given the fact that these are malformations and not true neoplasms and that they are entirely devoid of malignant potential, treatment should be aimed at maximizing the patient's function. In addition, treatment that results in a loss of function should not be tolerated. Early involvement of consultants can be helpful in meeting the goal of maximizing the patient's function and determining an optimal treatment plan.

- Incision and drainage
  - Limit incision and drainage to emergent decompression of a lesion.
  - This procedure does not eliminate the lesion but decreases the risk of infection.
- Surgical excision
  - Surgical excision remains the standard for treatment of lymphatic malformations, although many lesions are especially difficult to remove entirely because of their involvement with important neural and muscular structures; thus, these lesions are associated with the highest risk of recurrence and complications.
  - Recurrence rates of 20-40% are typically reported after surgical excision when the surgeon believes that the lesion is removed in its entirety.<sup>6</sup>
  - Complications of surgical excision of suprahyoid and oral lesions are also common. These operations can be difficult undertakings because of the diffuse infiltrative nature of the lesions and the difficulty in determining normal tissue from abnormal tissue.
  - Complication rates typically are 20-30%. Complications include airway obstruction, seromas and hematomas, infections, and cranial nerve palsies. Moreover, the reported operative mortality rates are 2.5-11.4%.
  - Surgical debulking, as part of a staged intervention plan, may be useful with large lingual malformations. Surgical debulking may obviate long-term tracheostomy, facilitate feeding, improve speech, and simplify further treatment, regardless of the modality used.
  - Surgical excision of macrocystic lesions may be facilitated by instilling fibrin glue into the cysts after partial aspiration of cystic contents.
- Laser therapy
  - Surface laser photocoagulation is used as an adjunct for controlling the size of the tongue, treating superficial lesions, and controlling bleeding.
  - Good results are reported. With the exception of isolated superficial lesions, surface laser photocoagulation does not lead to a cure.
  - Repeated hospital admissions for laser photocoagulation are not unusual. Some patients undergo as many as 25 procedures, which can be a significant burden on the patient and his or her family. This consideration is important because the patient is already consulting with multiple specialists and undergoing multiple procedures.
  - Results appear to be equivalent regardless of whether carbon dioxide, argon, or Nd:YAG lasers are used.
- Orthognathic surgery
  - Maxillofacial skeletal deformities and malocclusions should be treated with combined orthognathic and osteoplastic surgical procedures. Lesions of the upper part of the neck and, particularly, the floor of the mouth tend to be associated with bony overgrowth leading to class III malocclusions and open bite deformities. These lesions usually require combined surgical and orthodontic correction.
  - Orthognathic surgery is usually delayed until growth is complete, except in patients in whom the severity of the deformity necessitates earlier intervention.
- Sclerotherapy<sup>7,8</sup>
  - Myriad agents are used as sclerosing agents in attempts to avoid surgery and its attendant problems or to treat remnant lesions after partial excision.
    - The use of bleomycin has produced some impressive results. Good or excellent results (ie, tumor disappeared and did not recur with 3-8 injections or fewer, respectively) occur in 75-100% of patients, depending on the dominant histologic pattern of the lesion. Pulmonary fibrosis (the worst complication)

generally occurs only when cumulative doses exceed 450 mg. The 50-mg doses used in this therapy have not resulted in pulmonary fibrosis. Adverse effects include fever and anorexia lasting 24 hours in about 10% of patients. No adverse effects on growth and development are reported.

- Tissucol, a fibrin sealant, is reported to induce a high rate of remission in lymphatic malformations. Adverse effects are not observed, though a potential for infectious disease transmission exists. Even superficial lesions can be successfully treated, although multiple injections (as many as 3) are often required.
  - Ethibloc, a synthetic sclerosing agent, has been used to induce lesion regression. The complete regression rate is 60%, with minimal complications.
  - OK-432, a lyophilized incubation mixture of group A *Streptococcus pyogenes* of human origin treated with penicillin G, has been in sclerotherapy since the mid-1980s. Total or marked shrinkage is observed in 67% of lesions. OK-432 stimulates an intense inflammatory response that causes cystic spaces to shrink and preserves the endothelium with no scar formation. OK-432 may enhance the permeability of the endothelium, facilitating decompression. Adverse effects include a transient fever for 2-3 days after the injection and irritation at the injection site.<sup>9</sup>
- Repeated injections of sclerosing agents are often required, and resolution usually occurs over 1-4 months.
  - Macrocystic lesions are most amenable to sclerotherapy, followed by microcystic lesions and then superficial lesions.
  - Sclerotherapy does not represent an advantage compared with surgical ablation, with respect to success and ease of treatment. Success rates vary considerably depending on the agent used. Generally, boiling water, sodium morrhuate, tetracycline, 50% dextrose, and steroids are not effective in treating lymphatic malformations.
  - The encouraging results reported with sclerotherapy in conjunction with its low complication rate favor its adoption into the treatment protocols for lymphatic malformation, either as a stand-alone modality or as an adjunct to surgery.

## Consultations

- Anesthesiologist: Preoperative consultation with an anesthesiologist is often necessary for planning perioperative airway management.
- Speech pathologist
  - Preoperative assessment by a speech pathologist can help in identifying patients with deranged swallowing mechanics and in optimizing speech patterns.
  - The speech pathologist's input can help determine the need for and timing of intervention.
  - Postoperative consultation is often necessary for correcting any accumulated speech pathology and for managing rehabilitation, which is particularly important when lesions involve the tongue and soft palate.
  - Early involvement of speech pathologists and audiologists can help in identifying problems early in the course of the disease (see Complications). These specialists can aid in optimizing the patient's treatment plan.
- Pediatric dentist and orthodontist
  - Consultation is warranted to optimize the health and development of the patient's dentition.
  - Consultation with an orthodontist is warranted when orthognathic surgery is planned for the correction of maxillofacial skeletal deformities.
  - Pediatric dentists should be involved early in the care of children with oral lymphangiomas. Regular dental prophylaxis (q4-6mo) should be aggressively pursued to minimize the likelihood of developing an odontogenic source for infection of the malformation (see Complications).
- Dietitian
  - Dietitians should address the perioperative feeding of the patient before surgery is performed.
  - A dietitian can help in educating the patient and his or her family.
- Otolaryngologist and/or audiologist
  - Otolaryngologists are instrumental in the assessment and management of lesions involving the lower airway. Tracheostomy is required in as many as 50% of infants with cervicofacial lymphatic malformations. Tracheostomy places a tremendous burden on the child and family and, significantly, negatively impairs the child's quality of life. Decannulation should be aggressively pursued as part of the multidisciplinary management of the lesion.
  - When lesions involve the soft palate, the potential for eustachian tube dysfunction exists.

- Because consultants may identify hearing deficits that could result, they aid in determining the need for and timing of intervention.

## Diet

Depending on the location and size of the lesion, a variety of enteral feeding modalities may be required.

- Short-term bypass feeding while convalescing from surgery is most easily accomplished by using a nasogastric feeding tube.
- When prolonged (>4-6 wk) feeding difficulties are anticipated, a feeding gastrostomy is typically preferred.
- When an oral diet is permitted, patients typically begin with a clear liquid diet until approximately 2 weeks after surgery or longer if complications delay wound healing.

## Activity

Activity restrictions depend on the extent of the lesion.

- Patients in whom only superficial lesions are removed do not require activity restriction.
- Patients undergoing major debulking of larger lesions are generally advised to refrain from strenuous activity for approximately 4-6 weeks.

## Follow-up

### Inpatient & Outpatient Medications

- Perioperative antibiotic prophylaxis
  - Typically, prophylaxis with clindamycin 150-300 mg PO q6h to cover oral flora for 14 days is used after surgery involving larger, bulkier lesions.
  - Prophylaxis is not used in treating superficial lesions.

## Complications

- The severity of the sequelae varies with the extent of the lesion.
- Airway compromise is a possible complication.
  - Oral and hypopharyngeal lesions often result in a compromised airway. Approximately 50% of children with oral lymphangiomas require tracheotomy. Close cooperation between the surgeon and an anesthesiologist skilled in fiberoptic intubation is imperative.
  - The surgeon must be cognizant that these lesions may later expand and compromise the airway as a result of trauma, hemorrhage, infection, or upper respiratory tract infection. Surgeons should have a low threshold for performing a tracheostomy in patients in whom the potential for airway compromise exists.<sup>10</sup>
  - When a tracheostomy is not performed after a lesion on the tongue or floor of mouth has been debulked, the author prefers to manage the airway expectantly. The patient is left intubated overnight and reevaluated for extubation in the subsequent days.
- Dental caries are proportionately prevalent in these patients with oral lymphangiomas and are most likely a result of patient's and dentist's difficulties in maintaining adequate oral hygiene. The finding of dental caries is important because the spread of odontogenic infection to a lymphatic malformation is potentially life threatening. Additionally, the premature loss of dentition can further hamper proper nutrition in an already compromised patient. Therefore, aggressive dental care and meticulous hygiene are warranted. Pediatric dentists should be involved early in the care of children with oral lymphangioma.

- Dymorphogenesis of the maxillofacial skeleton is frequently observed in association with oral and cervicofacial malformations.
  - The proposed etiologies for these changes include local pressure effects, increased blood flow, and direct bony involvement. Bony changes appear to progress until growth is complete, regardless of whether the soft-tissue lesions are treated. In other words, soft-tissue debulking does not appear to affect the progression of this deformity; this finding appears to support the direct bony involvement hypothesis because debulking eliminates local pressure and blood flow effects. In addition, the bony overgrowth appears to behave as a malformation, mirroring somatic growth trends.
  - Although no histologic evidence suggests the presence of lymphatics in the long bones, lymphatics appear to be present in the alveolar bone of the mandible and maxilla. Histologic examination of resected mandibular specimens reveals abnormal dilated channels in marrow spaces lined by a flat, adult-type endothelium; this observation further supports the direct bony involvement hypothesis.
- Speech pathologies are common. These may result from abnormal morphology and mobility of the tongue, poor oral compliance, lip incompetence, and palatal hypomobility. Palatal hypomobility may contribute to eustachian tube dysfunction with resultant ear infections and conductive hearing deficits.
- Feeding difficulties are common in neonates. Alternate enteral feeding routes, including a gastrostomy, are often necessary.
- Repeated paroxysms of bleeding may occur secondary to trauma. These repeated paroxysms can be nuisances with superficial lesions, they can be life threatening with the expansion of deep lesions. Because the lesion is not lethal as long as airway compromise is avoided, the reported surgical mortality rates are 2.5-11.4%.
- Complications can result from surgical treatment.
- Complication rates of surgical debulking are typically 20-30%. Complications include airway obstruction, seromas and hematomas, infections, and cranial nerve palsies. Reported surgical mortality rates are 2.5-11.4%.

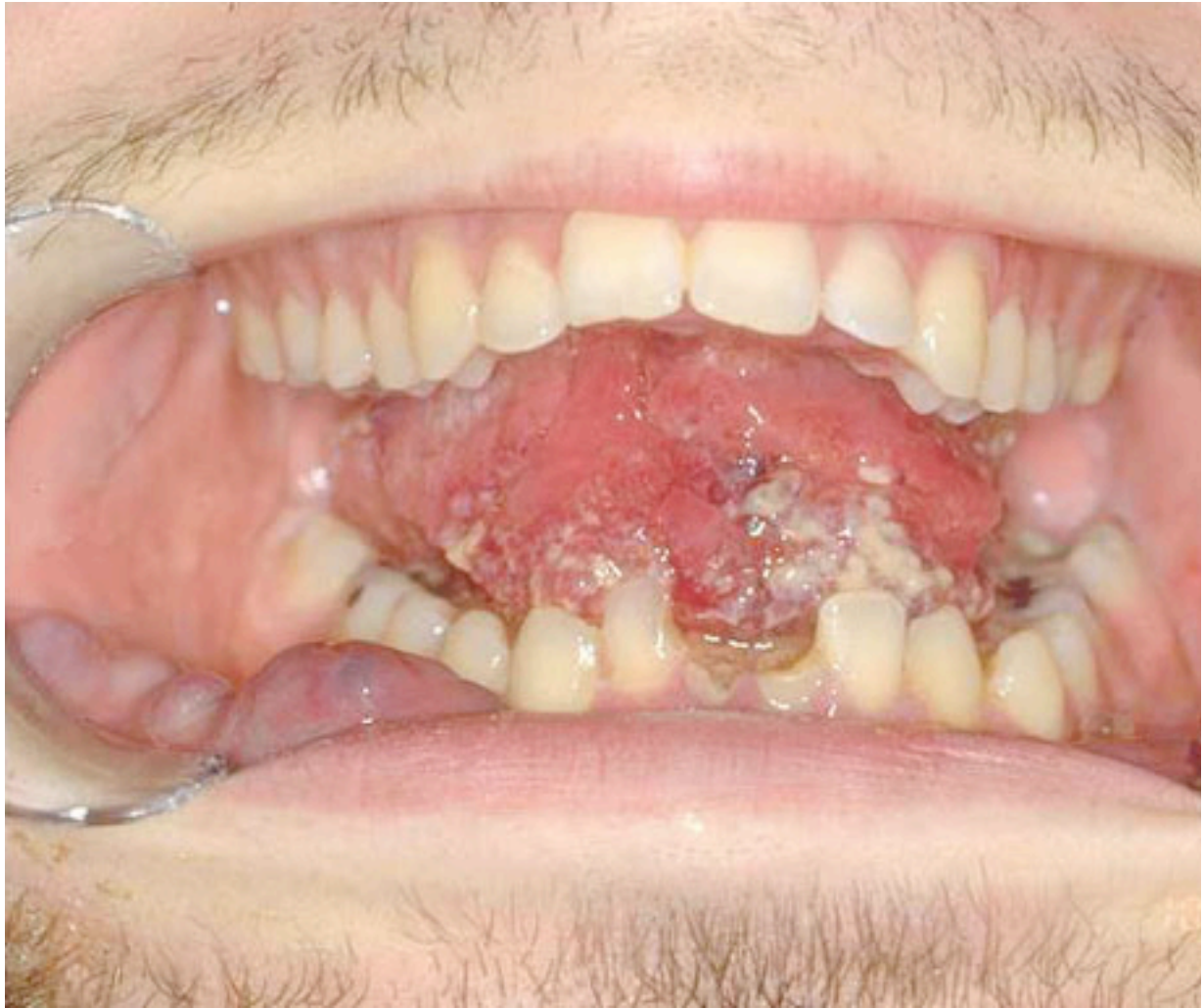## Miscellaneous

### Medicolegal Pitfalls

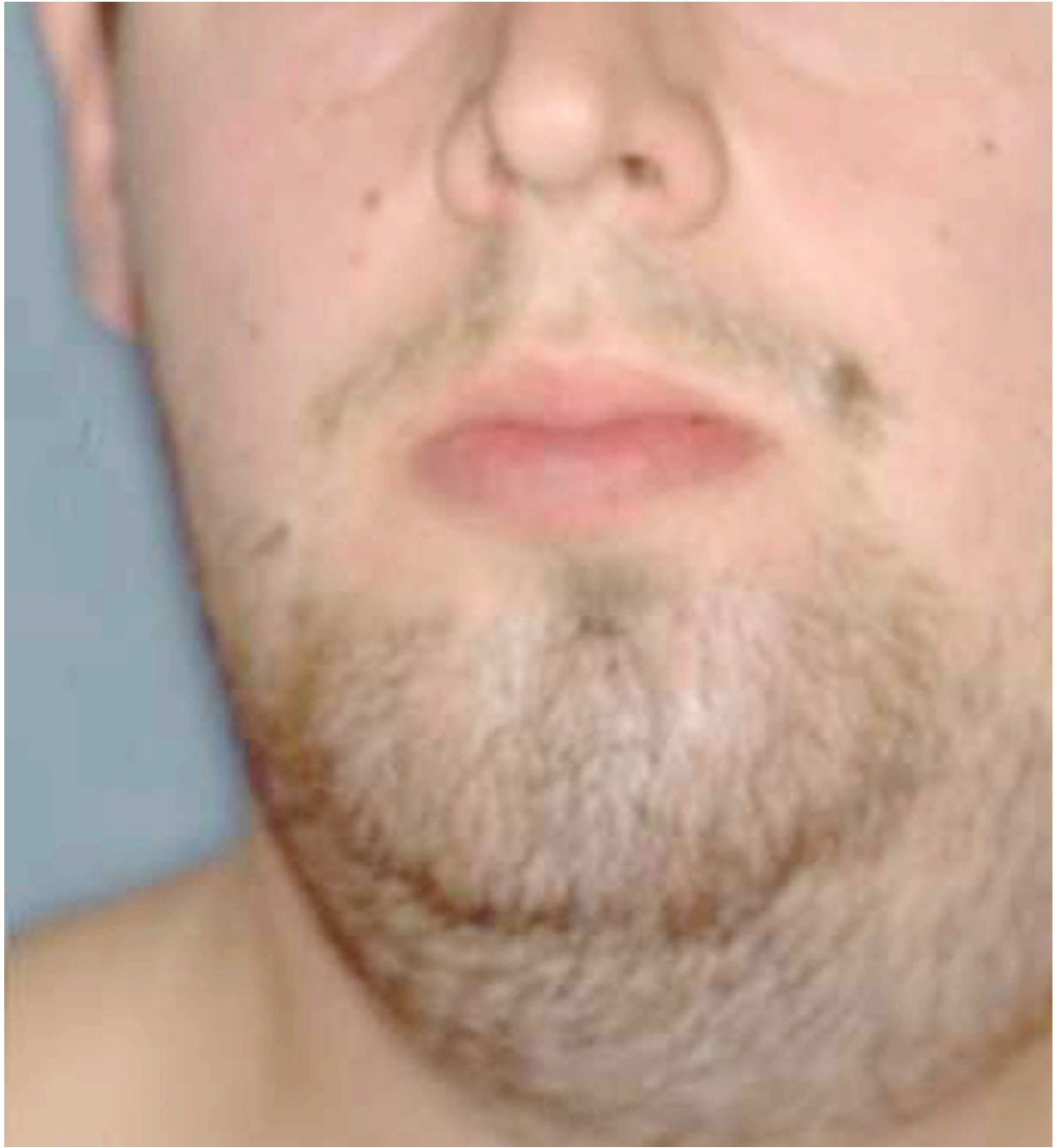- In sclerotherapy, adhering to a single treatment modality and failing to consider potential therapeutic modalities available is a pitfall.

## Multimedia

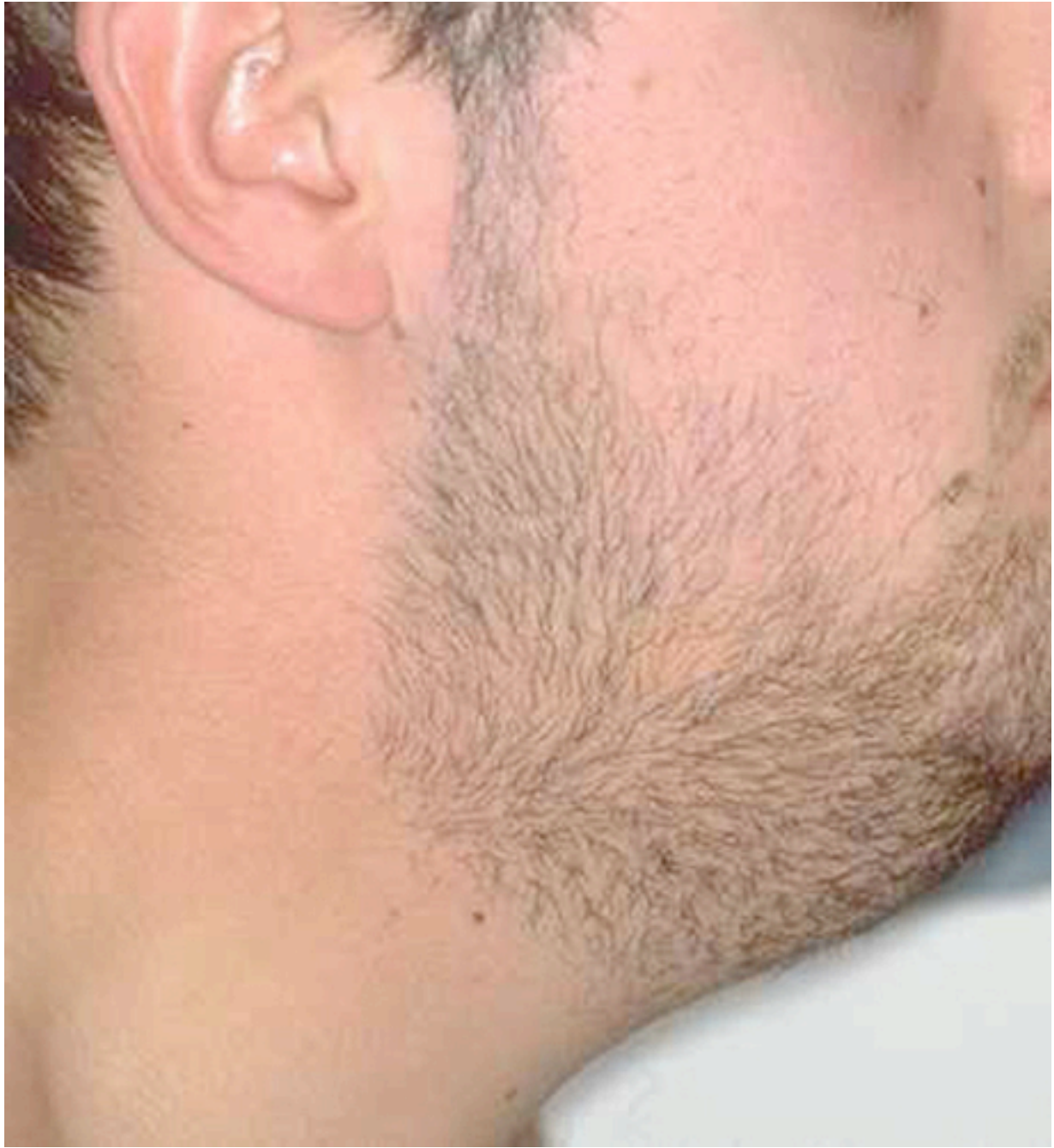



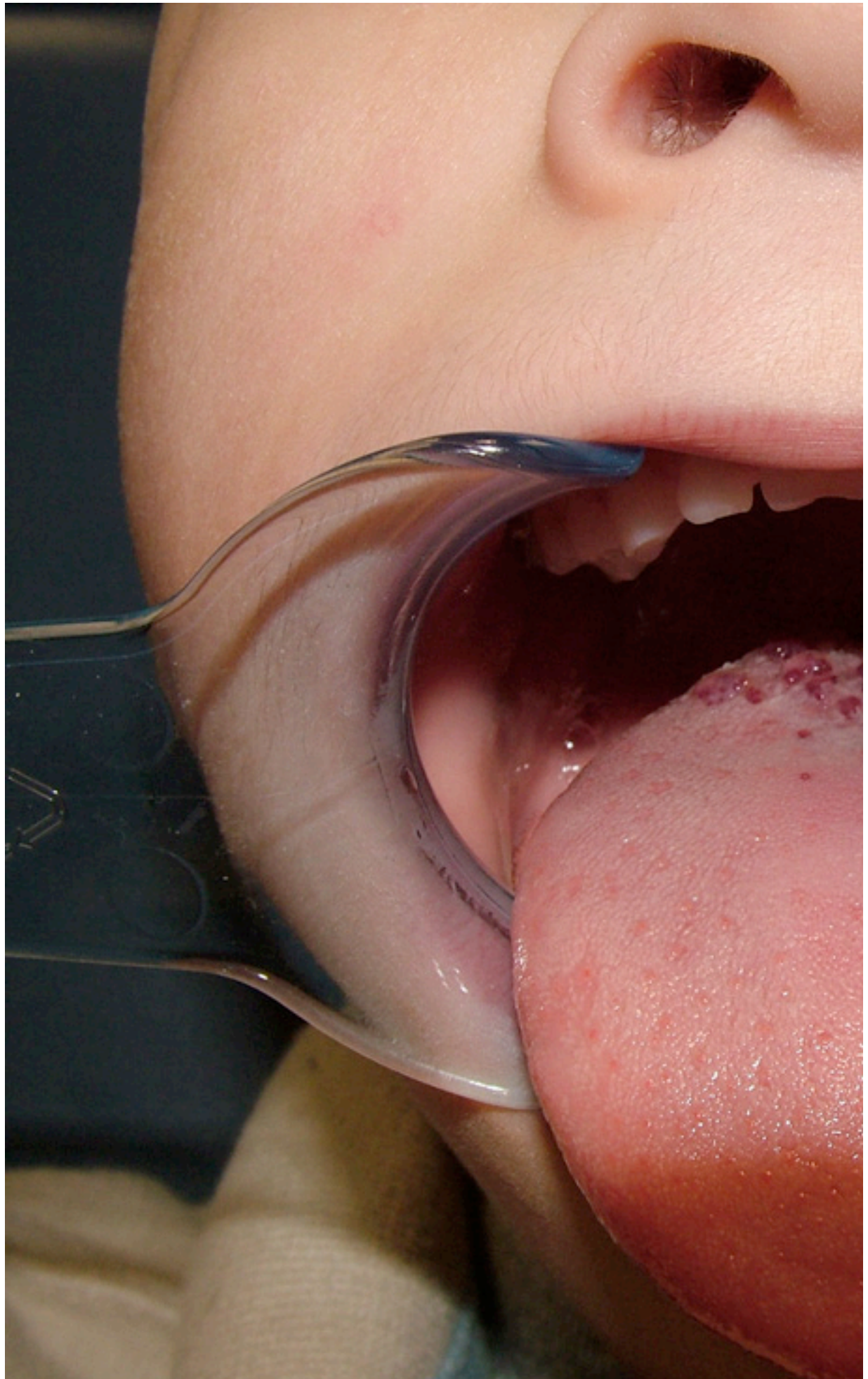
**Media file 1: Marked lingual enlargement caused by lymphatic malformation. Note the pebbly surface in areas not covered by materia alba. Also note the ecchymotic lesions protruding from the buccal mucosa in the mandibular vestibules.**



**Media file 2: Note the significant left buccal and submandibular swelling.**



**Media file 3: Profile view of a young adult with oral lymphangioma (same patient as in Media File 2).**



**Media file 4: Superficial lymphatic malformation.**