

eMedicine Specialties > Dermatology > Bullous Diseases

Pemphigus Herpetiformis

Lawrence Chan, MD, Department Head and Director of Skin Immunology Research, Professor, Departments of Dermatology and Microbiology/Immunology, University of Illinois College of Medicine

Updated: Oct 15, 2008

Introduction

Background

Pemphigus herpetiformis is a clinical variant of pemphigus that combines the clinical features of dermatitis herpetiformis with the immunopathologic features of pemphigus. Previously, pemphigus was described using various terms, including herpetiform pemphigus, acantholytic herpetiform dermatitis, pemphigus controlled by sulfapyridine, and mixed bullous disease. Because pemphigus herpetiformis is a clinical variant of pemphigus, it may be more appropriately described with a term that begins with the general group term (pemphigus), followed by a term for the variant subset (herpetiformis), similar to the terms for other pemphigus variants, such as pemphigus vulgaris, pemphigus foliaceus, pemphigus erythematosus, and pemphigus vegetans.

Pathophysiology

Pemphigus herpetiformis appears to be mediated by the immunoglobulin G (IgG) class of autoantibodies that target the skin epidermis desmoglein components. Most patients demonstrate autoantibodies to desmoglein 1, a desmosomal component predominantly located in the upper epidermis, while a minority of patients demonstrates autoantibodies to desmoglein 3, which is predominantly located in the lower epidermis. The ability of desmoglein 3 to induce an experimental model of pemphigus after transfer of splenocytes from desmoglein 3-immunized desmoglein 3-knockout mice to Rag-2 immunodeficient mice further supports the role of desmogleins as autoantigens. Histologically demonstrated eosinophil and/or neutrophil infiltration into the epidermis may be relevant pathogenically in the disease process.¹

In the neutrophil-dominant subset, epidermal cells secrete a neutrophil chemokine interleukin 8 (IL-8), which apparently is induced by IgG autoantibodies to desmoglein and may be responsible for the recruitment of neutrophils to the epidermis, resulting in the subsequent blistering process.

Frequency

United States

Pemphigus herpetiformis is a rare clinical variant of pemphigus. Frequency of occurrence remains undetermined.

International

Although frequency of occurrence is not determined, pemphigus herpetiformis has been reported in Europe, Japan, and the United States. In a large study conducted in Eastern Europe, 15 patients (7.3%) with pemphigus herpetiformis were found among 205 patients with pemphigus. In a smaller study conducted in Italy, 5 patients with pemphigus herpetiformis were found among 84 patients with pemphigus. Therefore, pemphigus herpetiformis accounts for approximately 6-7% of pemphigus in European populations.

Mortality/Morbidity

Pemphigus herpetiformis is not associated with significant mortality; however, the disease is associated with significant pruritus. Treatment regimens for the disease may cause significant adverse effects that must be monitored closely by the patient's physicians. Severe pruritus is noted in approximately one half of patients affected with pemphigus herpetiformis. At least 2 cases of pemphigus herpetiformis have been reported to occur in association with lung cancer. Whether this association was coincidental is not clear.^{2,3} In addition, pemphigus herpetiformis has been associated with prostate cancer development in one case.⁴

Race

Because pemphigus herpetiformis is rare, ethnic distribution is not determined yet. Because the disease occurs in the United States, Europe, and Asia, it does not appear to have a specific ethnic predominance.

Sex

Because pemphigus herpetiformis is rare, sex distribution is not determined yet. Subject: Pemphigus Herpetiformis: [Print] - eMedicine Dermatology Date: Fri, 4 Sep 2009 00:41:23 +0200 MIME-Version: 1.0 Content-Type: multipart/related; type="text/html"; boundary="-----_NextPart_000_0110_01CA2CF8.6DD07510" X-MimeOLE: Produced By Microsoft MimeOLE V6.00.2900.5579 This is a multi-part message in MIME format. -----_NextPart_000_0110_01CA2CF8.6DD07510 Content-Type: text/html; charset="Windows-1252" Content-Transfer-Encoding: quoted-printable Content-Location: <http://emedicine.medscape.com/article/1064550-print>



emedicine.medscape.com

eMedicine Specialties > Dermatology > Bullous Diseases

Pemphigus Herpetiformis

Lawrence Chan, MD, Department Head and Director of Skin Immunology Research, Professor, Departments of Dermatology and Microbiology/Immunology, University of Illinois College of Medicine

Updated: Oct 15, 2008

Introduction

Background

Pemphigus herpetiformis is a clinical variant of pemphigus that combines the clinical features of dermatitis herpetiformis with the immunopathologic features of pemphigus. Previously, pemphigus was described using various terms, including herpetiform pemphigus, acantholytic herpetiform dermatitis, pemphigus controlled by sulfapyridine, and mixed bullous disease. Because pemphigus herpetiformis is a clinical variant of pemphigus, it may be more appropriately described with a term that begins with the general group term (pemphigus), followed by a term for the variant subset (herpetiformis), similar to the terms for other pemphigus variants, such as pemphigus vulgaris, pemphigus foliaceus, pemphigus erythematosus, and pemphigus vegetans.

Pathophysiology

Pemphigus herpetiformis appears to be mediated by the immunoglobulin G (IgG) class of autoantibodies that target the skin epidermis desmoglein components. Most patients demonstrate autoantibodies to desmoglein 1, a desmosomal component predominantly located in the upper epidermis, while a minority of patients demonstrates autoantibodies to desmoglein 3, which is predominantly located in the lower epidermis. The ability of desmoglein 3 to induce an experimental model of pemphigus after transfer of splenocytes from desmoglein 3-immunized desmoglein 3-knockout mice to Rag-2 immunodeficient mice further supports the role of desmogleins as autoantigens. Histologically demonstrated eosinophil and/or neutrophil infiltration into the epidermis may be relevant pathogenically in the disease process.¹

In the neutrophil-dominant subset, epidermal cells secrete a neutrophil chemokine interleukin 8 (IL-8), which apparently is induced by IgG autoantibodies to desmoglein and may be responsible for the recruitment of neutrophils to the epidermis, resulting in the subsequent blistering process.

Frequency

United States

Pemphigus herpetiformis is a rare clinical variant of pemphigus. Frequency of occurrence remains undetermined.

International

Although frequency of occurrence is not determined, pemphigus herpetiformis has been reported in Europe, Japan, and the United States. In a large study conducted in Eastern Europe, 15 patients (7.3%) with pemphigus herpetiformis were found among 205 patients with pemphigus. In a smaller study conducted in Italy, 5 patients with pemphigus herpetiformis were found among 84 patients with pemphigus. Therefore, pemphigus herpetiformis accounts for approximately 6-7% of pemphigus in European populations.

Mortality/Morbidity

Pemphigus herpetiformis is not associated with significant mortality; however, the disease is associated with significant pruritus. Treatment regimens for the disease may cause significant adverse effects that must be monitored closely by the patient's physicians. Severe pruritus is noted in approximately one half of patients affected with pemphigus herpetiformis. At least 2 cases of pemphigus herpetiformis have been reported to occur in association with lung cancer. Whether this association was coincidental is not clear.^{2,3} In addition, pemphigus herpetiformis has been associated with prostate cancer development in one case.⁴

Race

Because pemphigus herpetiformis is rare, ethnic distribution is not determined yet. Because the disease occurs in the United States, Europe, and Asia, it does not appear to have a specific ethnic predominance.

Sex

Because pemphigus herpetiformis is rare, sex distribution has yet to be defined clearly. Studies in the literature do not appear to support a sex predilection.

Age

The age of onset for pemphigus herpetiformis ranges from 30-80 years, with a mean age of onset of 60 years.

Clinical

History

Patients affected with pemphigus herpetiformis usually have a subacute onset of disease. Approximately one half of patients experience severe pruritus.

Physical

- Patients affected with pemphigus herpetiformis usually present with erythematous, vesicular, bullous, or papular lesions.
- Lesions often demonstrate a "herpetiform" pattern, which is manifested as a cluster of blisters on an inflammatory base.
- Mucous membrane involvement is observed only occasionally. Oral erosion has been reported as a rare finding.
- Occasionally, lesions resemble those found in dermatitis herpetiformis, bullous pemphigoid, linear IgA bullous dermatosis, pemphigus foliaceus, pemphigus erythematosus, or pemphigus vulgaris.

Causes

- Pemphigus herpetiformis appears to be mediated by IgG autoantibodies targeting the interepidermal cell adhesion molecules desmoglein 1 or desmoglein 3.^{5,6,7} However, unlike typical pemphigus vulgaris, significant numbers of inflammatory cells, eosinophils, neutrophils, or mixed eosinophils and neutrophils infiltrate pemphigus herpetiformis lesional skin. The roles of inflammatory cells, particularly eosinophils, in the pathogenesis of pemphigus herpetiformis require further investigation.
- Etiology in the neutrophil-dominant subset of pemphigus herpetiformis includes the following:
 - In a study of 2 patients, IgG autoantibodies that recognized desmoglein 1 (a predominant upper-epidermal protein) exclusively were found to co-localize with expression of IL-8 (a strong neutrophil chemokine) and neutrophilic infiltration at the upper epidermis of the patients' skin.
 - In the study of 2 patients, the purified IgG fraction of the patients' sera induced IL-8 secretion from normal cultured human keratinocytes. Purified IgG from one of these patients also induced the cytoplasmic expression of IL-8 in normal cultured human keratinocytes.
 - Thus, in the neutrophil-dominant subset of pemphigus herpetiformis, it seems that IgG autoantibodies targeting desmoglein 1 were responsible for neutrophil recruitment to the epidermis as a result of inducing epidermal-cell IL-8 expression and secretion. Once at the epidermis, infiltrating neutrophils may result in blisters by releasing their proteases.
- In the eosinophil-dominant subset of pemphigus herpetiformis, eosinophilic involvement has not been investigated yet.
- One report of a patient with pemphigus herpetiformis has been associated with use of medication (thiopronine). A detailed mechanism is not delineated.⁸
- One patient with pemphigus herpetiformis had a history of psoriasis and developed the pemphigus disease shortly after a course of ultraviolet light treatment, raising a possible role of ultraviolet light in the induction of pemphigus herpetiformis.⁹
- At least 2 reported patients with pemphigus herpetiformis had coexisting psoriasis,¹⁰ a chronic inflammatory dermatosis, raising a possible role of "epitope spreading" in the induction of pemphigus herpetiformis.¹¹

Differential Diagnoses

Bullous Pemphigoid

Dermatitis Herpetiformis

Pemphigus Erythematosus

Pemphigus Foliaceus

Pemphigus Vulgaris

Other Problems to Be Considered

Linear immunoglobulin A bullous dermatosis

Workup

Laboratory Studies

- To establish a diagnosis of pemphigus herpetiformis, perform the following tests: histopathology on newly blistered skin, direct immunofluorescence (DIF) on periblistered skin, and indirect immunofluorescence (IIF) of the patient's sera on monkey esophagus substrate.
- Histopathology: Histopathology documents the acantholytic process and inflammatory cell infiltration (eosinophils, neutrophils, or both) that characterize the disease.
- Direct immunofluorescence
 - DIF documents the immunologic nature of the disease.
 - DIF usually detects the presence of IgG with or without C3 deposition around cell surfaces of keratinocytes in the patient's skin. The optimal location for the skin biopsy used in this study is adjacent to a blister or an inflammatory papule.
- Indirect immunofluorescence
 - IIF confirms the presence in the patient's serum of IgG-circulating autoantibodies that bind to epidermal cell surfaces.
 - In some patients, IgG autoantibodies predominantly bind to the upper part of the epidermis; in other patients, IgG autoantibodies bind to the entire epidermis.
 - The titer of autoantibodies often parallels the clinical level of activity of the disease and often is helpful in following the patient's disease activity after the diagnosis has been established.

Imaging Studies

- Patients who have associated pulmonary symptoms should undergo routine chest radiography. CT scanning may also be needed.

Other Tests

- Immunoblotting¹²
 - Immunoblotting documents specific skin desmosomal components, in a denatured form, that are recognized by the patient's IgG autoantibodies.
 - Most patients with pemphigus herpetiformis have IgG autoantibodies that recognize desmoglein 1, a desmosomal protein predominantly located in the upper epidermis.
 - In a minority of patients with pemphigus herpetiformis, IgG autoantibodies were detected to desmoglein 3, a desmosomal protein predominantly located in the lower epidermis.
- Enzyme-linked immunosorbent assay¹³
 - Similar to immunoblotting, enzyme-linked immunosorbent assay (ELISA) detects the specific protein component (usually in recombinant nondenatured form) recognized by the patient's IgG autoantibodies.
 - ELISA usually is more sensitive than immunoblotting in detecting the protein recognized by autoantibodies.
- Immunoprecipitation: Immunoprecipitation has the same function as immunoblotting but is more difficult to perform. Immunoprecipitation detects the native form of the target antigen rather than the denatured form of the antigen.

Treatment

Medical Care

Pemphigus herpetiformis is responsive to anti-inflammatory and immunosuppressive medications. Dapsone is the drug of choice if the patient tolerates the treatment. In severe cases that do not respond to conventional treatments (systemic corticosteroid and immunosuppressives), the physicians could also consider using a monoclonal antibody anti-CD20 (rituximab), which has specific actions against B lymphocytes. Rituximab has shown very good clinical efficacy for patients with pemphigus vulgaris, a form of pemphigus that is usually more severe than pemphigus herpetiformis.

A related article posted on Medscape is "Advances in Pemphigus Therapy."

Activity

No specific activity restrictions are indicated; however, advise patients to avoid injury during the active disease period.

Medication

Because pemphigus herpetiformis is a rare variant of pemphigus, comprehensive therapeutic studies of large numbers of patients have not taken place. The following treatment options are taken from the personal experiences of physician-investigators with a small number of patients.

In general, dapsone is the drug of choice. Other anti-inflammatory and immunosuppressive medications are also effective.

Anti-inflammatories

Since pemphigus herpetiformis lesions are characterized by prominent infiltration of inflammatory cells, anti-inflammatory medication may inhibit the functions of these cells, therefore improving disease conditions.

Dapsone (Avlosulfon)

Mechanism of action is similar to that of sulfonamides, in which competitive antagonists of PABA prevent formation of folic acid, inhibiting bacterial growth. Used alone or in conjunction with other anti-inflammatory medication or immunosuppressives for pemphigus herpetiformis.

Dosing

Adult

100 mg PO qd or 50 mg PO bid

Pediatric

>10 years: 25-50 mg/d PO single dose or 25-50 mg/d PO bid; consult pediatrician before prescribing

Interactions

Trimethoprim, probenecid, and folic acid antagonists (eg, pyrimethamine, methotrexate) increase levels; activated charcoal, PABA, and rifampin decrease levels; may increase hemolysis with sulfonamides and hydroxychloroquine

Contraindications

Absolute: Documented hypersensitivity

Relative: G-6-PD deficiency (especially in African Americans, persons of Middle Eastern heritage, Asians), significant cardiopulmonary disease, significant hematologic disease, sulfa allergy (cautious use may be attempted; cross-reactivity is relatively rare and mild)

Precautions

Pregnancy

C - Fetal risk revealed in studies in animals but not established or not studied in humans; may use if benefits outweigh risk to fetus

Precautions

Perform weekly CBC counts (first mo), then perform CBC counts monthly (6 mo), then semiannually; discontinue if significant reduction in platelets, leukocytes, or hematopoiesis is seen; methemoglobin reductase deficiency, G-6-PD deficiency, or hemoglobin M because of high risk for hemolysis and Heinz body formation; patients exposed to other agents or conditions (eg, infection, diabetic ketosis) capable of producing hemolysis; peripheral neuropathy can occur (rare); phototoxicity may occur when exposed to UV light

Prednisone (Deltasone)

Immunosuppressant for treatment of autoimmune disorders; may decrease inflammation by reversing increased capillary permeability and suppressing PMN activity. Stabilizes lysosomal membranes and also suppresses lymphocytes and antibody production. Taken alone, or in conjunction with other anti-inflammatory or immunosuppressive medications, is useful for controlling pemphigus herpetiformis.

Dosing

Adult

20-60 mg PO qam; taper over 2-4 wk as symptoms resolve; alternatively, 0.5-2 mg/kg/d; taper as condition improves; single morning dose is safer for long-term use, but divided doses have more anti-inflammatory effect

Pediatric

4-5 mg/m²/d PO, or 0.05-2 mg/kg PO; taper over 2 wk as symptoms resolve; consult pediatrician before prescribing

Interactions

Increased levels occur with ketoconazole, erythromycin, clarithromycin, estrogens, and birth control pills; decreased levels occur with aminoglutethimide, phenytoin, phenobarbital, rifampin, cholestyramine, and ephedrine; levels of potassium-depleting diuretics (potentiates potassium loss and digitalis toxicity) and cyclosporine increase; levels of isoniazid, insulin (resistance is induced), and salicylates decrease; monitor anticoagulant therapy and theophylline levels

Contraindications

Absolute: Systemic fungal infection, herpes simplex keratitis, hypersensitivity (usually with corticotropin, occasionally with IV forms)

Relative: Hypertension, active TB, CHF, prior psychosis, positive purified protein derivative test result, glaucoma, severe depression, diabetes mellitus, active peptic ulcer disease, cataracts, osteoporosis, recent bowel anastomosis, pregnancy

Precautions

Pregnancy

C - Fetal risk revealed in studies in animals but not established or not studied in humans; may use if benefits outweigh risk to fetus

Precautions

Use lower dose in hypothyroidism, liver disease, and obesity (decreased cortisol-binding globulin [CBG] and increased free fraction of steroid); pregnancy, hyperthyroidism, and concurrent estrogen therapy may increase CBG levels; abrupt discontinuation of glucocorticoids may cause adrenal crisis; hyperglycemia, edema, osteonecrosis, myopathy, peptic ulcer disease, hypokalemia, osteoporosis, euphoria, psychosis, myasthenia gravis, growth suppression, and infections may occur with glucocorticoid use; alternate-day therapy does not prevent bone loss (appropriate monitoring and prophylaxis for osteoporosis continues to evolve)

Immunosuppressives

Pemphigus herpetiformis is an autoimmune disease; immunosuppressives are useful in suppressing autoimmune response.

Azathioprine (Imuran)

Antagonizes purine metabolism and inhibits synthesis of DNA, RNA, and proteins. May decrease proliferation of immune cells, which results in lower autoimmune activity. Usually used as supplement to anti-inflammatory medication; is useful in controlling pemphigus herpetiformis.

Dosing

Adult

1 mg/kg qd/bid (empiric) or by TPMT level; increase by 0.5 mg/kg q4wk until response, not to exceed 2.5 mg/kg/d

TPMT testing not entirely reliable; involves testing activity of TPMT activity in RBCs, which correlates with systemic TPMT activity; functional enzyme test has been shown to have variability between test sites, and kits may contain varying amounts of enzyme inhibitor; starting at low doses, monitoring for pancytopenia, then increasing the dose is an alternative; if clinical response is not good, patient may be a homozygote for high activity and may need increased dose; some references recommend checking before treatment in all patients

TPMT <5 U: No treatment with azathioprine

TPMT 5-13.7 U: Not to exceed 0.5 mg/kg

TPMT 13.7-19 U: Not to exceed 1.5 mg/kg

TPMT >19 U: Not to exceed 2.5 mg/kg

Pediatric

Safety and efficacy not established

Interactions

Allopurinol increases risk of pancytopenia; captopril/ACE inhibitors may increase risk of anemia and leukopenia; warfarin dose may need to be increased; pancuronium dose may need to be increased for adequate paralysis; live virus vaccines and cotrimoxazole increase risk of hematologic toxicity; rifampicin may cause transplants to possibly be rejected; clozapine may increase risk of agranulocytosis

Contraindications

Absolute: Documented hypersensitivity, pregnancy or attempting pregnancy, clinically significant active infection

Relative: Concurrent use of allopurinol; prior treatment with alkylating agents (eg, cyclophosphamide, chlorambucil, melphalan, others [high risk of neoplasia])

Precautions

Pregnancy

D - Fetal risk shown in humans; use only if benefits outweigh risk to fetus

Precautions

Increased risk of neoplasia; caution in liver disease and renal impairment; hematologic toxicities may occur; rarely, patients may develop fever without associated infections; measure thiopurine methyltransferase level prior to treatment; periodically monitor CBC count and liver function

Biological Response Modulator

Rituximab (Rituxan)

Genetically engineered chimeric murine/human monoclonal antibody against human CD20, a molecule present in normal and malignant B lymphocytes. Described in case reports as a promising biological treatment for B-lymphocyte-mediated diseases (eg, pemphigus vulgaris).

Dosing

Adult

375 mg/m² skin surface area IV weekly for 4 consecutive weeks, followed by monthly infusion of same dose for 4 consecutive months

Pediatric

Not established

Interactions

Renal toxicity observed in combination with cisplatin

Contraindications

Documented hypersensitivity; documented anaphylaxis or IgE-mediated hypersensitivity reaction to murine proteins or their components

Precautions

Pregnancy

C - Fetal risk revealed in studies in animals but not established or not studied in humans; may use if benefits outweigh risk to fetus

Precautions

Monitor CBC and platelet counts regularly during and few months posttreatment for occurrence of cytopenia; monitor human antichimeric antibody development (approximately 1% patients); monitor and treat associated infections (30% probability)

Severe infusion reactions have occurred, typically during the first infusion, with time to onset of 30-120 minutes; signs and symptoms may include urticaria, hypotension, angioedema, hypoxia, or bronchospasm and may require interruption of infusion; the most severe manifestations and sequelae include pulmonary infiltrates, acute respiratory distress syndrome, myocardial infarction, ventricular fibrillation, cardiogenic shock, and anaphylactic and anaphylactoid events

Factors most commonly associated with fatal outcomes are female sex, pulmonary infiltrates, and chronic lymphocytic leukemia or mantle cell lymphoma; infusions should be interrupted for severe reactions and medication and supportive care measures provided; in most cases, the infusion can be resumed at a 50% reduction in rate when symptoms have completely resolved

Tumor lysis syndrome (TLS): Rapid reduction in tumor volume followed by acute renal failure, hyperkalemia, hypocalcemia, hyperuricemia, or hyperphosphatemia has been reported within 12-24 h after the first infusion; risk greater in patients with high numbers of circulating malignant cells ($>25,000/\mu\text{L}$) or high tumor burden; following complete resolution of TLS complications, rituximab has been tolerated when re-administered in conjunction with prophylactic therapy for TLS

Hepatitis B virus (HBV): Reactivation with related fulminant hepatitis and other viral infections

HBV reactivation with related fulminant hepatitis, hepatic failure and death have been reported in some patients with hematologic malignancies; most patients received rituximab in combination with chemotherapy; median time to diagnosis of hepatitis was approximately 4 mo after initiation of rituximab and approximately 1 mo after last dose; patients who develop viral hepatitis should have rituximab and any concomitant chemotherapy discontinued; appropriate treatment should be initiated; data regarding safety of resuming rituximab in patients who develop hepatitis subsequent to HBV reactivation is insufficient

Follow-up

Further Inpatient Care

The disease activities of pemphigus herpetiformis rarely require hospitalization. In a few patients, short-term hospitalization (<10 d) may be helpful.

Further Outpatient Care

The disease activities of pemphigus herpetiformis range from mild to moderate. During the active disease period, provide follow-up care for patients on a monthly outpatient basis. These visits ensure that (1) patients are responding clinically to prescribed medications and (2) patients experience no serious adverse effects that require a change of medications. Typically, follow-up visits are not needed for patients in clinical remission and not on treatment.

Deterrence/Prevention

For patients who are treated with systemic corticosteroid for longer than one month, a combined calcium and Vitamin D supplements should be instituted to prevent osteoporosis. The dosage and frequency of these supplements are stated in the 1996 recommendations established by the American College of Rheumatology Task Force.¹⁴

Prognosis

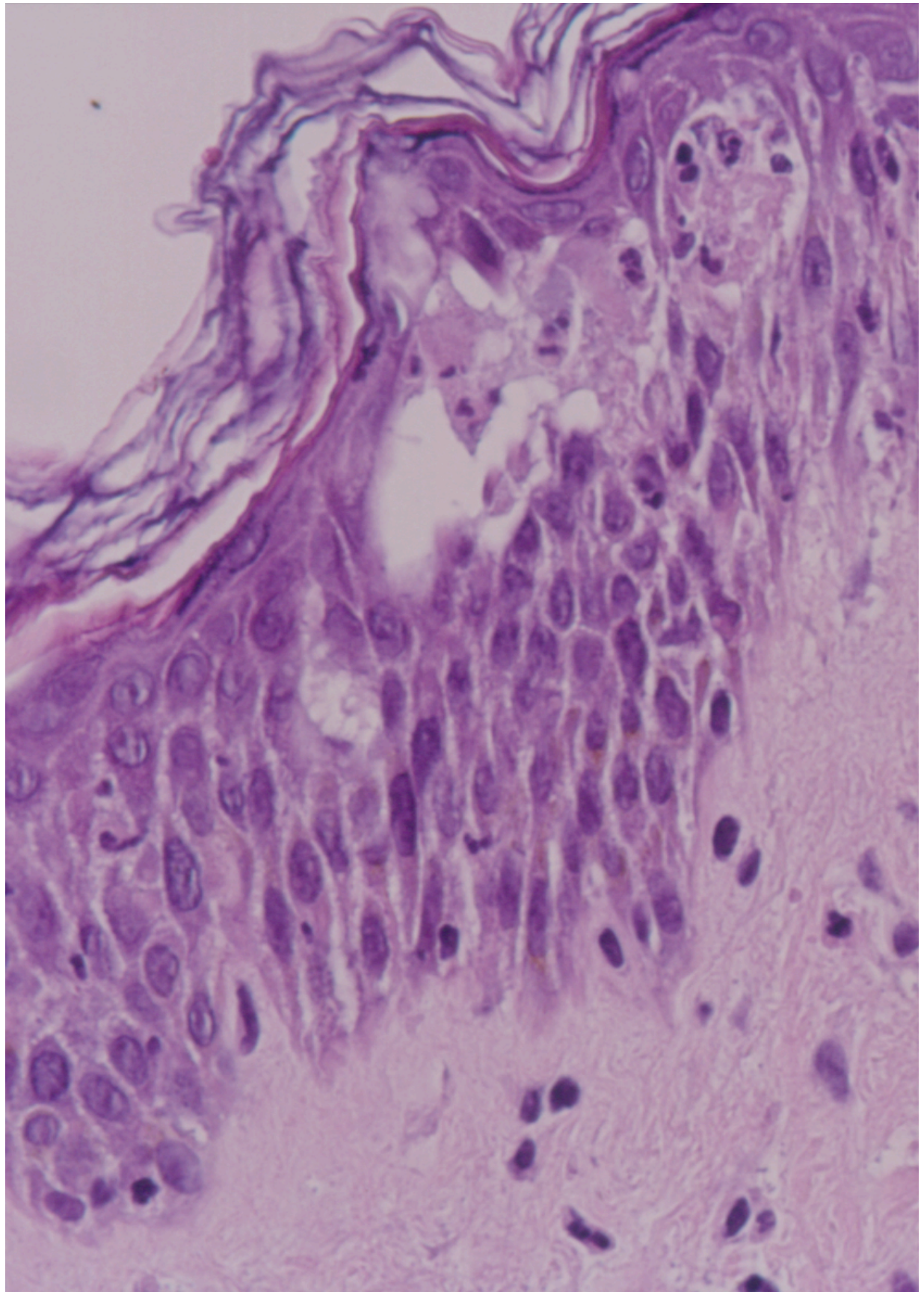
The prognosis for pemphigus herpetiformis usually is excellent.

Miscellaneous

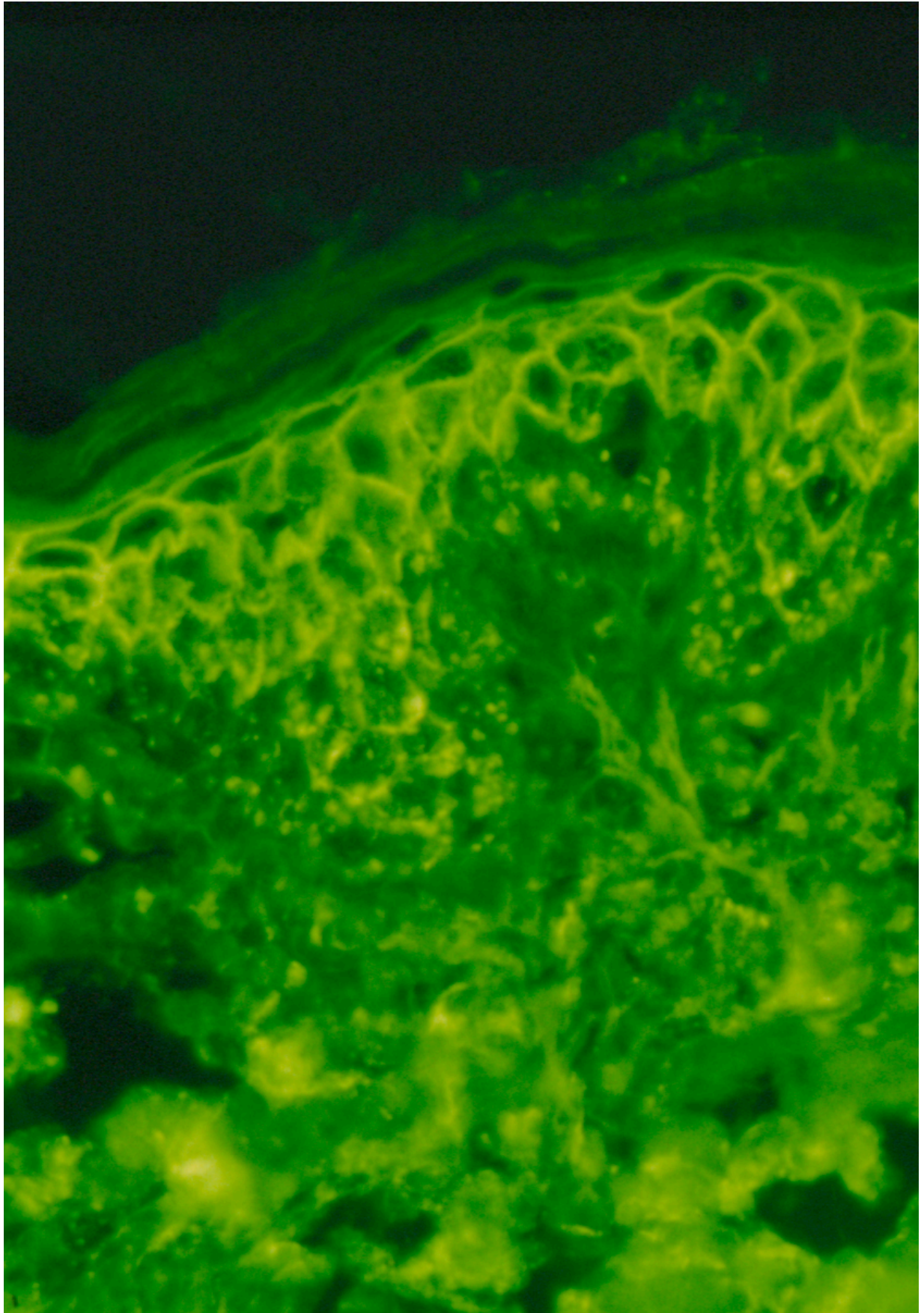
Medicolegal Pitfalls

- Failure to monitor patients receiving treatment with dapsone, since adverse effects may be severe
- Failure to examine early signs of neuropathy, which is essential in patients receiving treatment with dapsone because of potential adverse effects
- Failure to regularly obtain CBC counts, which is important in patients receiving treatment with dapsone to monitor potential adverse effects
- Failure to investigate potential lung cancer associated with the disease when the patient has pulmonary symptoms

Multimedia



Media file 1: Histopathologic examination of a blister lesion obtained from a patient with pemphigus herpetiformis shows a subcorneal blistering process, acantholysis, and neutrophilic infiltrate.



Media file 2: Direct immunofluorescence microscopy performed on a skin biopsy specimen obtained from a patient with pemphigus

herpetiformis detects immunoglobulin G deposits on the epithelial cell surfaces but sparing the basal layers.

References

1. Amagai M, Tsunoda K, Suzuki H, Nishifuji K, Koyasu S, Nishikawa T. Use of autoantigen-knockout mice in developing an active autoimmune disease model for pemphigus. *J Clin Invest*. Mar 2000;105(5):625-31. [Medline].
2. Kubota Y, Yoshino Y, Mizoguchi M. A case of herpetiform pemphigus associated with lung cancer. *J Dermatol*. Aug 1994;21(8):609-11. [Medline].
3. Palleschi GM, Giomi B. Herpetiformis pemphigus and lung carcinoma: a case of paraneoplastic pemphigus. *Acta Derm Venereol*. 2002;82(4):304-5. [Medline].
4. Marzano AV, Tourlaki A, Cozzani E, Gianotti R, Caputo R. Pemphigus herpetiformis associated with prostate cancer. *J Eur Acad Dermatol Venereol*. May 2007;21(5):696-8. [Medline].
5. Brod C, Fierlbeck G, Metzler G, Sönnichsen K, Röcken M, Schaller M. [Desmoglein 1-negative, desmoglein 3-positive pemphigus herpetiformis with involvement of oral mucous membranes]. *J Dtsch Dermatol Ges*. Apr 2005;3(4):280-2. [Medline].
6. Ishii K, Amagai M, Komai A, Ebihara T, Chorzeliski TP, Jablonska S, et al. Desmoglein 1 and desmoglein 3 are the target autoantigens in herpetiform pemphigus. *Arch Dermatol*. Aug 1999;135(8):943-7. [Medline].
7. Kubo A, Amagai M, Hashimoto T, Doi T, Higashiyama M, Hashimoto K, et al. Herpetiform pemphigus showing reactivity with pemphigus vulgaris antigen (desmoglein 3). *Br J Dermatol*. Jul 1997;137(1):109-13. [Medline].
8. Verdier-Sevrain S, Joly P, Thomine E, Belanyi P, Gilbert D, Tron F, et al. Thiopronine-induced herpetiform pemphigus: report of a case studied by immunoelectron microscopy and immunoblot analysis. *Br J Dermatol*. Feb 1994;130(2):238-40. [Medline].
9. Sanchez-Palacios C, Chan LS. Development of pemphigus herpetiformis in a patient with psoriasis receiving UV-light treatment. *J Cutan Pathol*. Apr 2004;31(4):346-9. [Medline].
10. Morita E, Amagai M, Tanaka T, Horiuchi K, Yamamoto S. A case of herpetiform pemphigus coexisting with psoriasis vulgaris. *Br J Dermatol*. Oct 1999;141(4):754-5. [Medline].
11. Chan LS, Vanderlugt CJ, Hashimoto T, Nishikawa T, Zone JJ, Black MM, et al. Epitope spreading: lessons from autoimmune skin diseases. *J Invest Dermatol*. Feb 1998;110(2):103-9. [Medline].
12. Hashimoto T, Ogawa MM, Konohana A, Nishikawa T. Detection of pemphigus vulgaris and pemphigus foliaceus antigens by immunoblot analysis using different antigen sources. *J Invest Dermatol*. Mar 1990;94(3):327-31. [Medline].
13. Ishii K, Amagai M, Hall RP, Hashimoto T, Takayanagi A, Gamou S, et al. Characterization of autoantibodies in pemphigus using antigen-specific enzyme-linked immunosorbent assays with baculovirus-expressed recombinant desmogleins. *J Immunol*. Aug 15 1997;159(4):2010-7. [Medline].
14. American College of Rheumatology. Recommendations for the prevention and treatment of glucocorticoid-induced osteoporosis. American College of Rheumatology Task Force on Osteoporosis Guidelines. *Arthritis Rheum*. Nov 1996;39(11):1791-801. [Medline].
15. Ahmed AR, Spigelman Z, Cavacini LA, Posner MR. Treatment of pemphigus vulgaris with rituximab and intravenous immune globulin. *N Engl J Med*. Oct 26 2006;355(17):1772-9. [Medline].
16. Amagai M, Klaus-Kovtun V, Stanley JR. Autoantibodies against a novel epithelial cadherin in pemphigus vulgaris, a disease of cell adhesion. *Cell*. Nov 29 1991;67(5):869-77. [Medline].
17. Barranco VP. Mixed bullous disease. *Arch Dermatol*. Aug 1974;110(2):221-4. [Medline].
18. DeMento FJ, Grover RW. Acantholy