

eMedicine Specialties > Dermatology > Bullous Diseases

Pemphigus Vulgaris

Bassam Zeina, MD, PhD, Consulting Staff, Department of Dermatology, Milton Keynes Hospital, UK
Sohail Mansoor, MBBS, MSc, Dermatologist and Lead Physician in Dermatologic Surgery, Department of Dermatology, Barnet Hospital, UK

Updated: Aug 14, 2009

Introduction

Background

Pemphigus is derived from the Greek word *pemphix* meaning bubble or blister. Pemphigus describes a group of chronic bullous diseases, originally named by Wichman in 1791. The term pemphigus once included most bullous eruptions of the skin, but diagnostic tests have improved, and bullous diseases have been reclassified.

The term pemphigus refers to a group of autoimmune blistering diseases of the skin and mucous membranes characterized histologically by intraepidermal blister and immunopathologically by the finding of in vivo bound and circulating immunoglobulin G (IgG) antibody directed against the cell surface of keratinocytes. The 3 primary subsets of pemphigus include pemphigus vulgaris (PV), pemphigus foliaceus, and paraneoplastic pemphigus. Each type of pemphigus has distinct clinical and immunopathologic features. PV accounts for approximately 70% of pemphigus cases.

Pathophysiology

PV is an autoimmune, intraepithelial, blistering disease affecting the skin and mucous membranes and is mediated by circulating autoantibodies directed against keratinocyte cell surfaces. In 1964, autoantibodies against keratinocyte surfaces were described in patients with pemphigus. Clinical and experimental observations indicate that the circulating autoantibodies are pathogenic. An immunogenetic predisposition is well established.

Blisters in PV are associated with the binding of IgG autoantibodies to keratinocyte cell surface molecules. These intercellular or PV antibodies bind to keratinocyte desmosomes and to desmosome-free areas of the keratinocyte cell membrane. The binding of autoantibodies results in a loss of cell-cell adhesion, a process termed acantholysis. The antibody alone is capable of causing blistering without complement or inflammatory cells.

PV antigen: Intercellular adhesion in the epidermis involves several keratinocyte cell surface molecules. Pemphigus antibody binds to keratinocyte cell surface molecules desmoglein 1 and desmoglein 3. The binding of antibody to desmoglein may have a direct effect on desmosomal adherens or may trigger a cellular process that results in acantholysis. Antibodies specific for nondesmosomal antigens also have been described in the sera of patients with PV; however, the role of these antigens in the pathogenesis of disease is not known.

Antibodies: Patients with active disease have circulating and tissue-bound autoantibodies of both the immunoglobulin G1 (IgG1) and immunoglobulin G4 (IgG4) subclasses.¹ Disease activity correlates with antibody titer in most patients.²

Complement: Pemphigus antibody fixes components of complement to the surface of epidermal cells. Antibody binding may activate complement with the release of inflammatory mediators and recruitment of activated T cells.

Frequency

United States

PV is uncommon, and the exact incidence and prevalence depends on the population studied.

International

PV has been reported to occur worldwide. PV incidence varies from 0.5-3.2 cases per 100,000. PV incidence is increased in patients of Ashkenazi Jewish descent and those of Mediterranean origin.

Mortality/Morbidity

PV is a potentially life-threatening autoimmune mucocutaneous disease with a mortality rate of approximately 5-15%. Complications secondary to the use of high-dose corticosteroids contribute to the mortality rate. Morbidity and mortality are related to the extent of disease, the maximum dose of systemic steroids required to induce remission, and the presence of other diseases. Prognosis is worse in patients with extensive disease and in older patients.

- PV involves mucosa in 50-70% of patients. This may limit oral intake secondary to dysphagia. Blistering
andalvato da Windows Internet Explorer 8> Subject: Pemphigus Vulgaris: [Print] - eMedicine Dermatology
Date: Fri, 4 Sep 2009 00:38:33 +0200 MIME-Version: 1.0 Content-Type: multipart/related; type="text/html";
boundary="-----_NextPart_000_00EE_01CA2CF8.0858CF70" X-MimeOLE: Produced By Microsoft
MimeOLE V6.00.2900.5579 This is a multi-part message in MIME format. -----
=_NextPart_000_00EE_01CA2CF8.0858CF70 Content-Type: text/html; charset="Windows-1252" Content-
Transfer-Encoding: quoted-printable Content-Location: [http://emedicine.medscape.com/article/1064187-
print](http://emedicine.medscape.com/article/1064187-print)



emedicine.medscape.com

eMedicine Specialties > Dermatology > Bullous Diseases

Pemphigus Vulgaris

Bassam Zeina, MD, PhD, Consulting Staff, Department of Dermatology, Milton Keynes Hospital,
UK

Sohail Mansoor, MBBS, MSc, Dermatologist and Lead Physician in Dermatologic Surgery,
Department of Dermatology, Barnet Hospital, UK

Updated: Aug 14, 2009

Introduction

Background

Pemphigus is derived from the Greek word *pemphix* meaning bubble or blister. Pemphigus describes a group of chronic bullous diseases, originally named by Wichman in 1791. The term pemphigus once included most bullous eruptions of the skin, but diagnostic tests have improved, and bullous diseases have been reclassified.

The term pemphigus refers to a group of autoimmune blistering diseases of the skin and mucous membranes characterized histologically by intraepidermal blister and immunopathologically by the finding of in vivo bound and circulating immunoglobulin G (IgG) antibody directed against the cell surface of keratinocytes. The 3 primary subsets of pemphigus include pemphigus vulgaris (PV), pemphigus foliaceus, and paraneoplastic pemphigus. Each type of pemphigus has distinct clinical and immunopathologic features. PV accounts for approximately 70% of pemphigus cases.

Pathophysiology

PV is an autoimmune, intraepithelial, blistering disease affecting the skin and mucous membranes and is mediated by circulating autoantibodies directed against keratinocyte cell surfaces. In 1964, autoantibodies against keratinocyte surfaces were described in patients with pemphigus. Clinical and experimental observations indicate that the circulating autoantibodies are pathogenic. An immunogenetic predisposition is well established.

Blisters in PV are associated with the binding of IgG autoantibodies to keratinocyte cell surface molecules. These intercellular or PV antibodies bind to keratinocyte desmosomes and to desmosome-free areas of the keratinocyte cell membrane. The binding of autoantibodies results in a loss of cell-cell adhesion, a process termed acantholysis. The antibody alone is capable of causing blistering without complement or inflammatory cells.

PV antigen: Intercellular adhesion in the epidermis involves several keratinocyte cell surface molecules. Pemphigus antibody binds to keratinocyte cell surface molecules desmoglein 1 and desmoglein 3. The binding of antibody to desmoglein may have a direct effect on desmosomal adherens or may trigger a cellular process that results in acantholysis. Antibodies specific for nondesmosomal antigens also have been described in the sera of patients with PV; however, the role of these antigens in the pathogenesis of disease is not known.

Antibodies: Patients with active disease have circulating and tissue-bound autoantibodies of both the immunoglobulin G1 (IgG1) and immunoglobulin G4 (IgG4) subclasses.¹ Disease activity correlates with antibody titer in most patients.²

Complement: Pemphigus antibody fixes components of complement to the surface of epidermal cells. Antibody binding may activate complement with the release of inflammatory mediators and recruitment of activated T cells.

Frequency

United States

PV is uncommon, and the exact incidence and prevalence depends on the population studied.

International

PV has been reported to occur worldwide. PV incidence varies from 0.5-3.2 cases per 100,000. PV incidence is increased in patients of Ashkenazi Jewish descent and those of Mediterranean origin.

Mortality/Morbidity

PV is a potentially life-threatening autoimmune mucocutaneous disease with a mortality rate of approximately 5-15%. Complications secondary to the use of high-dose corticosteroids contribute to the mortality rate. Morbidity and mortality are related to the extent of disease, the maximum dose of systemic steroids required to induce remission, and the presence of other diseases. Prognosis is worse in patients with extensive disease and in older patients.

- PV involves mucosa in 50-70% of patients. This may limit oral intake secondary to dysphagia. Blistering and erosions secondary to the rupture of blisters may be painful and limit the patient's daily activities.
- Patients with PV typically heal without scarring unless the disease is complicated by severe secondary infection.

Race

PV affects all races. The prevalence of PV is high in regions where the Jewish population is predominant.³ For example, in Jerusalem, the prevalence of PV was estimated at 1.6 cases per 100,000 population; in Connecticut, the prevalence was 0.42 cases per 100,000 population.⁴ Incidence of PV in Tunisia is estimated at 2.5 cases per million population per year (3.9 in women, 1.2 in men), while in France, the incidence is 1.3 cases per million population per year (no significant difference between men and women).⁵ In Finland, where few people of Jewish or Mediterranean origin live, the prevalence is low, at 0.76 cases per million population.⁶

Sex

Male-to-female ratio is approximately equal. In adolescence, girls are more likely to be affected than boys.

Age

Mean age of onset is approximately 50-60 years; however, the range is broad, and disease onset in older individuals and in children has been described. Patients are younger at presentation in India than in Western countries.⁷

Clinical

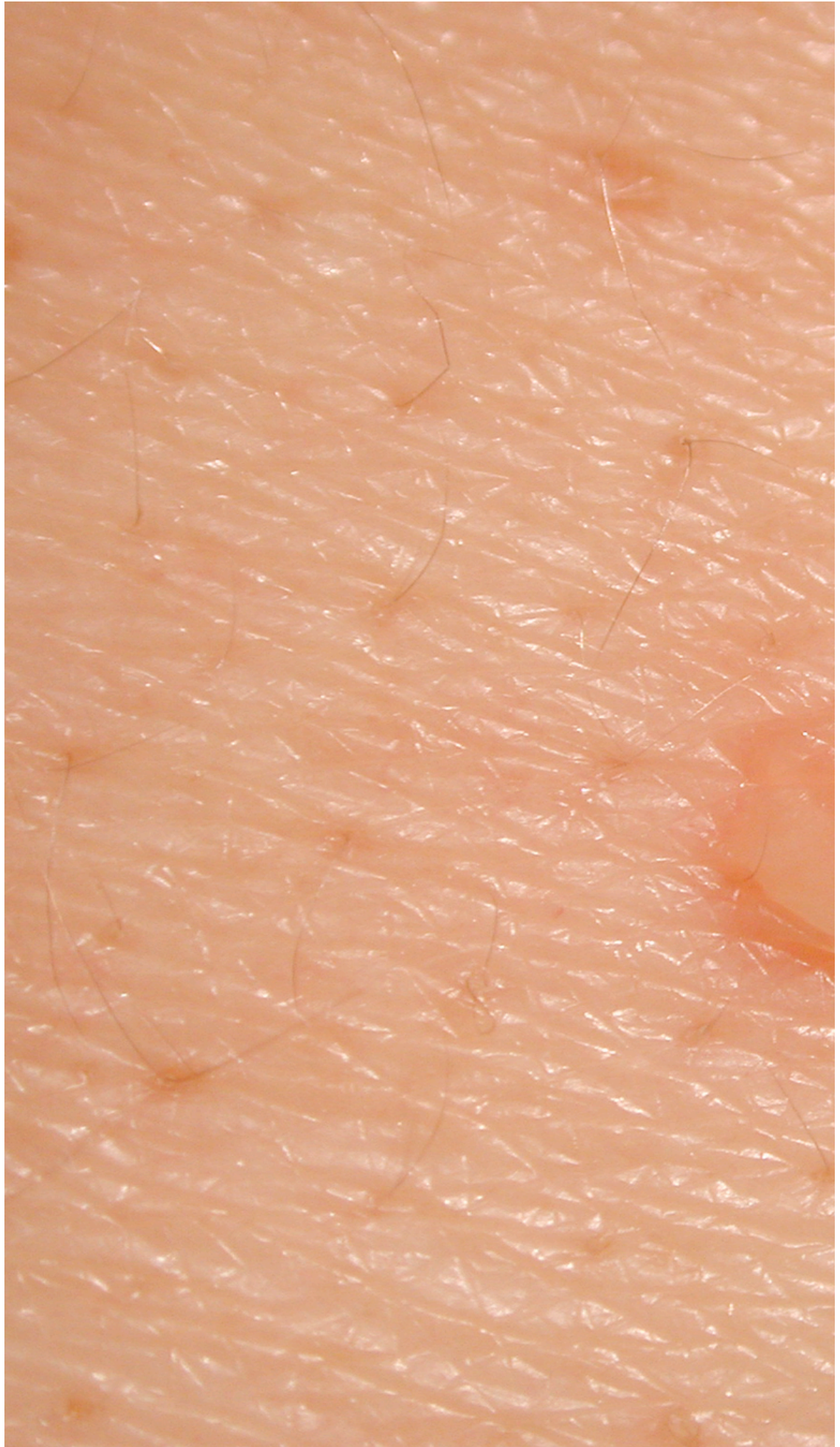History

- Mucous membranes: PV presents with oral lesions in 50-70% of patients, and almost all patients have mucosal lesions. Mucosal lesions may be the sole sign for an average of 5 months before skin lesions develop, or they may be the sole manifestation of the disease.
- Skin: Most patients develop cutaneous lesions. The primary lesion of PV is a flaccid blister, which usually arises on normal-appearing skin but may be found on erythematous skin. New blisters usually are flaccid or become flaccid quickly. Affected skin often is painful but rarely pruritic.
- Drug-induced PV: Drugs reported most significantly in association with PV include penicillamine, captopril, and other thiol-containing compounds. Rifampin and emotional stress have recently been reported as triggers for PV.⁸

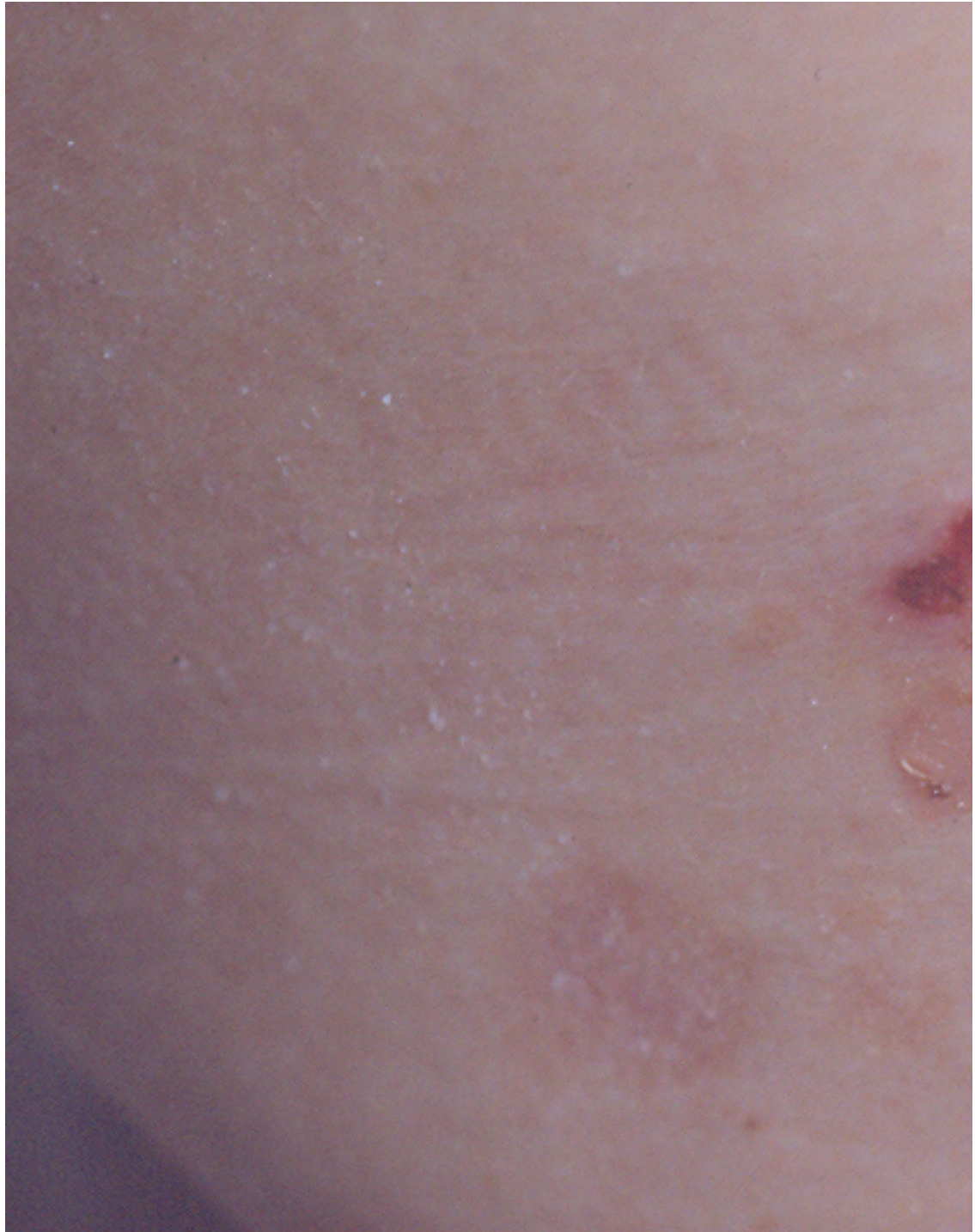
Physical

Mucous membranes typically are affected first in PV. Mucosal lesions may precede cutaneous lesions by months. Patients with mucosal lesions may present to dentists, oral surgeons, or gynecologists.

- Mucous membranes
 - Intact bullae are rare in the mouth. More commonly, patients have ill-defined, irregularly shaped, gingival, buccal or palatine erosions, which are painful and slow to heal. The erosions extend peripherally with shedding of the epithelium.
 - The mucous membranes most often affected are those of the oral cavity, which is involved in almost all patients with PV and sometimes is the only area involved. Erosions may be seen on any part of the oral cavity. Erosions can be scattered and often extensive. Erosions may spread to involve the larynx with subsequent hoarseness. The patient often is unable to eat or drink adequately because the erosions are so uncomfortable.
 - Other mucosal surfaces may be involved, including the conjunctiva,⁹ esophagus,¹⁰ labia, vagina, cervix, penis, urethra, and anus.
- Skin: The primary lesion of PV is a flaccid blister filled with clear fluid that arises on normal skin or on an erythematous base. The blisters are fragile; therefore, intact blisters may be sparse. The contents soon become turbid, or the blisters rupture producing painful erosions, which is the most common skin presentation. Erosions often are large because of their tendency to extend peripherally with the shedding of the epithelium.

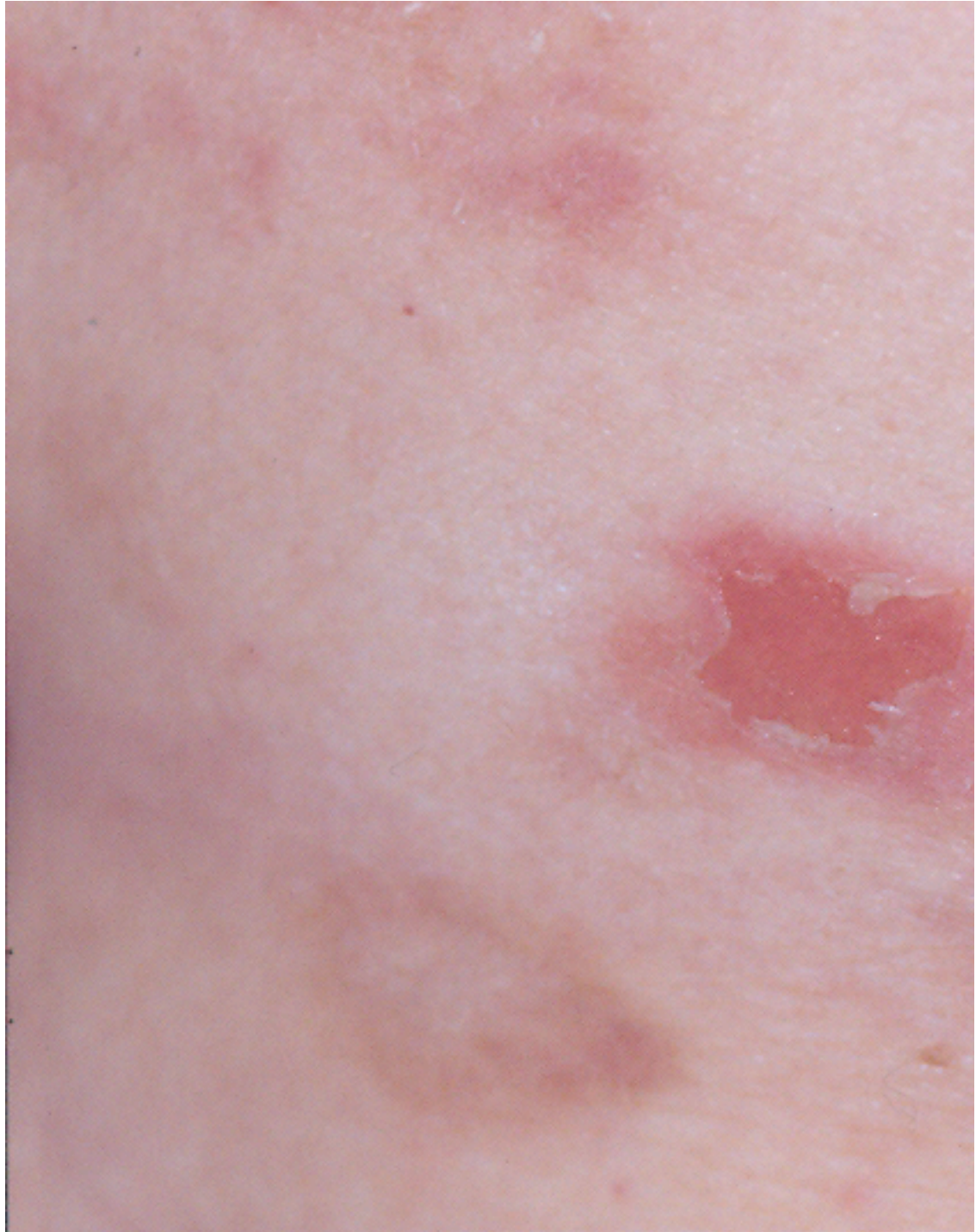

Early, small blister filled with clear fluid arises on healthy skin.



Flaccid blister filled with clear fluid arises on healthy skin.

- Vegetating PV: Ordinary PV erosions may develop vegetation. Lesions in skin folds readily form vegetating granulations. In some patients, erosions tend to develop excessive granulation tissue and crusting, and these patients display more vegetating lesions. This type of lesion tends to occur more frequently in intertriginous areas and on the scalp or face. The vegetating type of response can be more resistant to therapy and can remain in one place for long periods of time.



An erosion.

- Nails: Acute paronychia, subungual hematomas, and nail dystrophies have been reported with PV.^{11,12}
- Pemphigus in pregnancy: Occurrence in pregnancy is rare. When present, maternal autoantibodies may cross the placenta, resulting in neonatal pemphigus. Neonatal pemphigus is transient and improves with clearance of maternal autoantibodies.¹³
- Nikolsky sign: In patients with active blistering, firm sliding pressure with a finger separates normal-appearing epidermis, producing an erosion. This sign is not specific for PV and is found in other active blistering diseases.
- Asboe-Hansen sign: Lateral pressure on the edge of a blister may spread the blister into clinically unaffected skin.

Causes

The cause of PV remains unknown; however, several potentially relevant factors have been identified.

- Genetic factors: Predisposition to pemphigus is linked to genetic factors.¹⁴ Certain major histocompatibility complex (MHC) class II molecules, in particular alleles of human leukocyte antigen DR4 (DRB1*0402) and human leukocyte antigen DRw6 (DQB1*0503), are common in patients with PV.^{15,16,17,18}
- Age: Peak age of onset is from 50-60 years. Infants with neonatal pemphigus remit with clearance of maternal autoantibodies. The disease may present in childhood or in older persons.
- Disease association: Pemphigus occurs in patients with other autoimmune diseases, particularly myasthenia gravis and thymoma.¹⁹

Differential Diagnoses

Bullous Pemphigoid
Dermatitis Herpetiformis
Erythema Multiforme
Familial Benign Pemphigus (Hailey-Hailey Disease)
Linear IgA Dermatitis
Pemphigus Erythematosus
Pemphigus Foliaceus

Pemphigus Herpetiformis
Pemphigus, Drug-Induced
Pemphigus, IgA
Pemphigus, Paraneoplastic

Other Problems to Be Considered

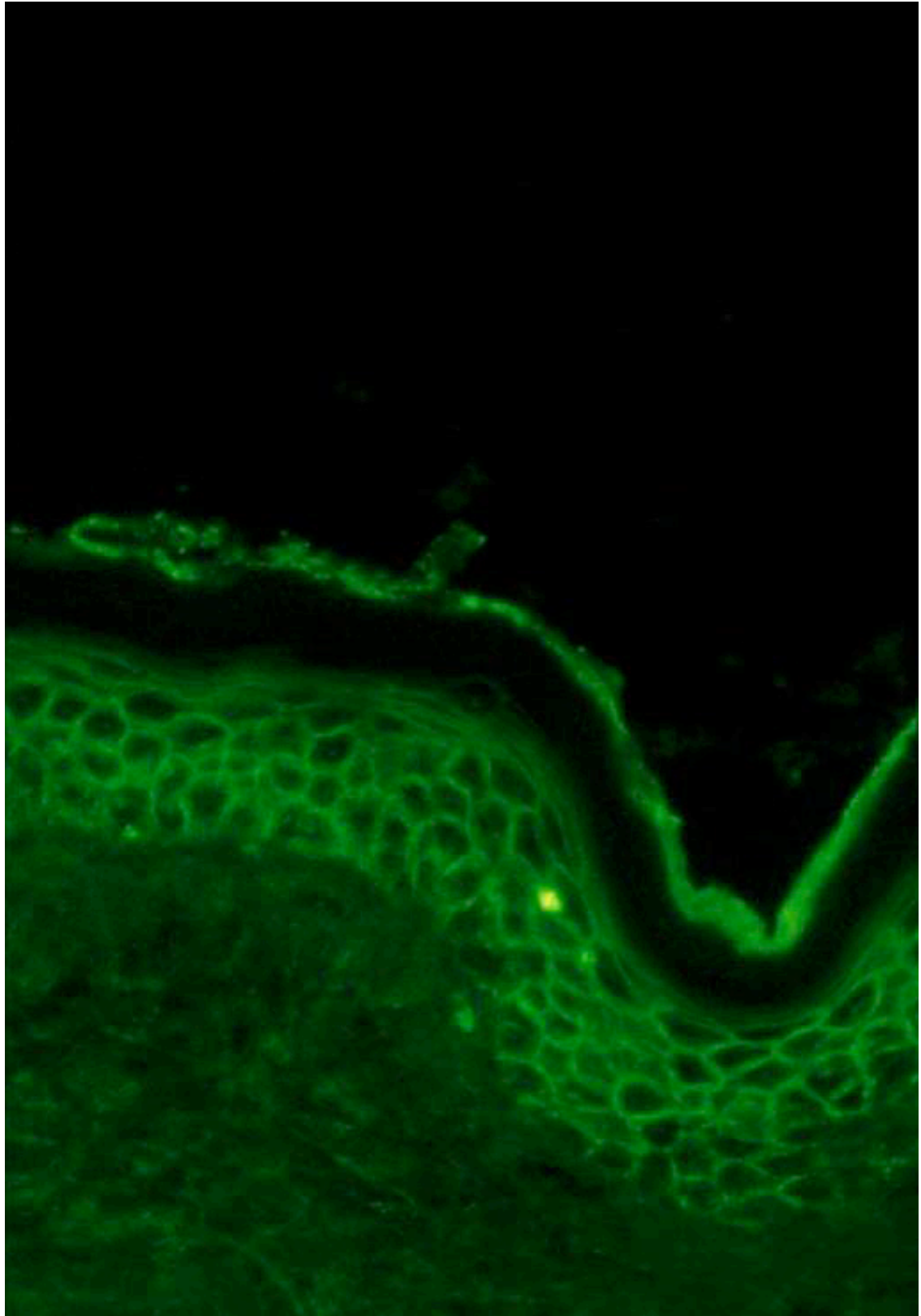
Erythema multiforme
Aphthous ulcers
Herpetic stomatitis
Bullous lichen planus

Workup

Laboratory Studies

- To establish a diagnosis of pemphigus vulgaris (PV), perform the following tests:
 - Histopathology from the edge of a blister
 - Direct immunofluorescence (DIF) on normal-appearing perilesional skin
 - Indirect immunofluorescence (IDIF) using the patient's serum if DIF is positive. The preferred substrate for IDIF is monkey esophagus or salt-split normal human skin substrate.

- DIF demonstrates in vivo deposits of antibodies and other immunoreactants, such as complement. DIF usually shows IgG deposited on the surface of the keratinocytes in and around lesions. IgG1 and IgG4 are the most common subclasses. Complement components such as C3 and immunoglobulin M are present less frequently than IgG. DIF shows intercellular deposition throughout the epidermis. This pattern of immunoreactants is not specific for PV and may be seen in pemphigus vegetans, pemphigus foliaceus, and pemphigus erythematosus. The best location for DIF is normal perilesional skin. When DIF is performed on lesional skin, false-positive results can be observed.



Direct immunofluorescence showing intercellular immunoglobulin G throughout the epidermis of a patient with pemphigus vulgaris.

- Skin biopsy specimens placed in transport media may yield false-negative results; therefore, fresh tissue is the preferred substrate for DIF studies.
- In the patient's serum, IDIF demonstrates the presence of circulating IgG autoantibodies that bind to epidermis. Circulating intercellular antibodies are detected using IDIF in 80-90% of patients with PV. The titer of circulating antibody correlates with disease course.²⁰

Histologic Findings

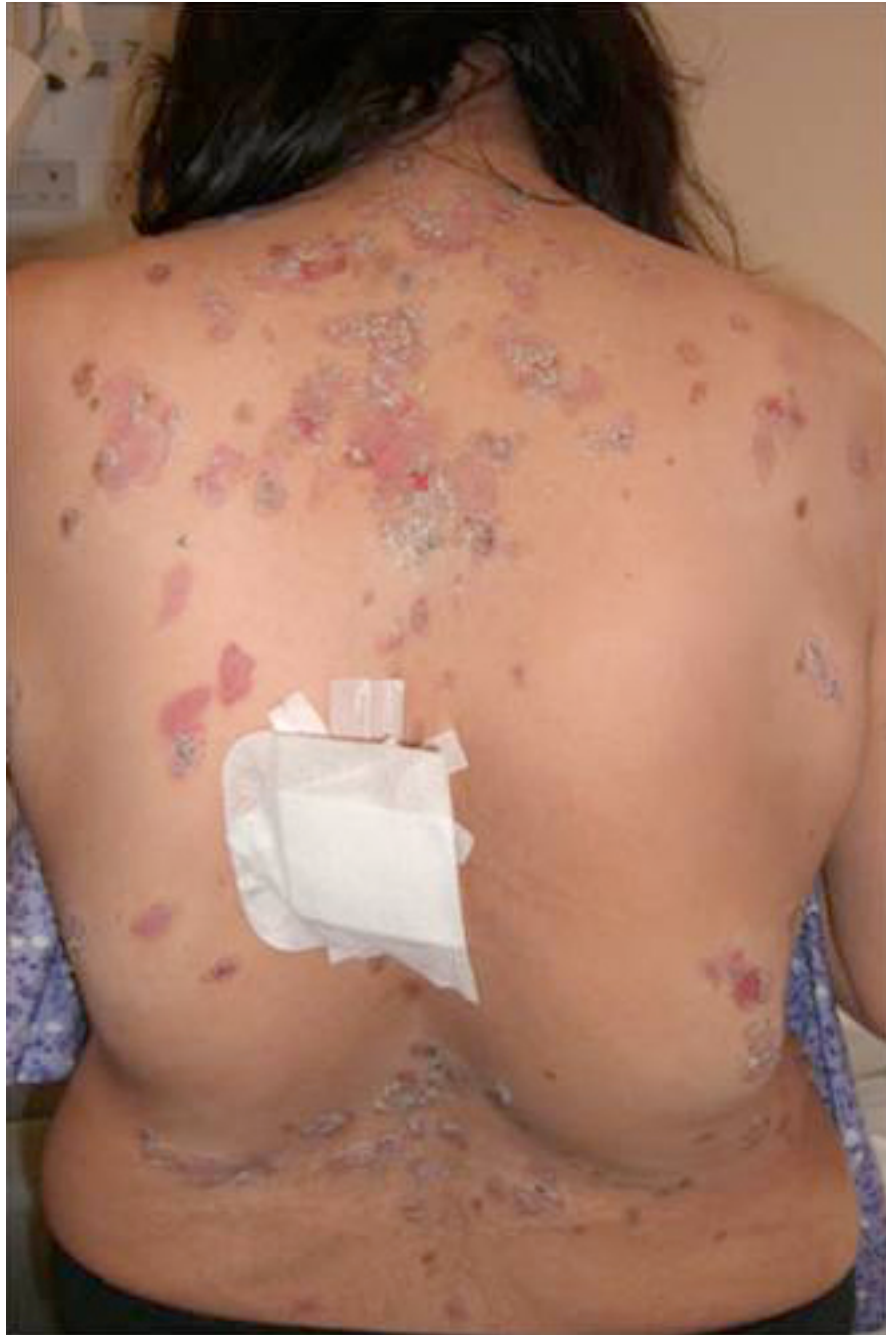Histopathology demonstrates an intradermal blister. The earliest changes consist of intercellular edema with loss of intercellular attachments in the basal layer. Suprabasal epidermal cells separate from the basal cells to form clefts and blisters. Basal cells are separated from one another and stand like a row of tombstones on the floor of the blister, but they remain attached to the basement membrane. Blister cells contain some acantholytic cells. Histopathology can help differentiate PV from pemphigus foliaceus, which demonstrates a more superficial epidermal cleavage.

Tzanck preparation is a smear taken from the base of a blister or an oral erosion that contains acantholytic cells. Blistering is preceded by eosinophilic spongiosis in some patients. The superficial dermis has a mild, superficial, mixed inflammatory infiltrate, which includes some eosinophils.

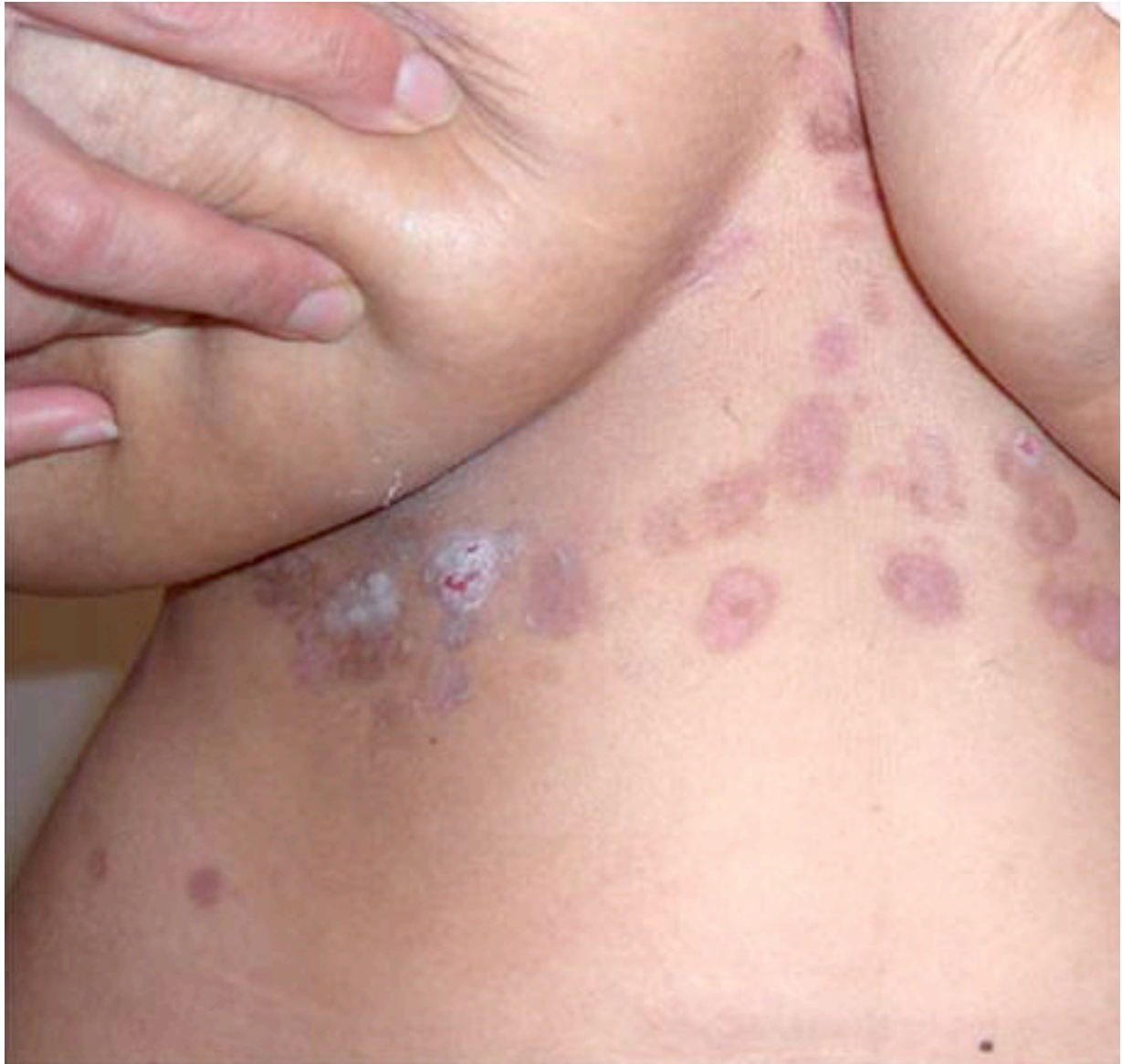Treatment

Medical Care

The aim of treatment in pemphigus vulgaris (PV) is the same as in other autoimmune bullous diseases, which is to decrease blister formation, promote healing of blisters and erosions, and determine the minimal dose of medication necessary to control the disease process. Therapy must be tailored for each patient, taking into account preexisting and coexisting conditions. Patients may continue to experience mild disease activity while under optimal treatment.



Erosions and healing areas on the back.



Healing areas on the chest and abdomen.

Corticosteroids have improved overall mortality, but now much of the mortality and morbidity in these patients relates to the adverse effects of therapy. Whether massive doses of steroids have any advantage over doses of 1 mg/kg/d is unclear. Immunosuppressive drugs are steroid sparing and should be considered early in the course of the disease. Epidermal growth factor may speed healing of localized lesions.²¹ Amagai et al reported on the successful use of intravenous immunoglobulin in pemphigus patients who did not fully respond to systemic steroids.²²

Consultations

Management of patients with PV requires coordination of care between the dermatologist and the patient's primary care physician.

- An ophthalmologist should evaluate patients with suspected ocular involvement and those requiring prolonged high-dose steroids.

- Patients with oral disease may require a dentist and/or an otolaryngologist for evaluation and care.
- Patients on systemic steroids should maintain adequate vitamin D and calcium intake through diet and supplements. Patients with a history of renal calculi should not receive calcium carbonate.
- Patients receiving long-term systemic corticosteroids should be evaluated by a rheumatologist within the first 30 days of treatment for osteoporosis risk assessment and consideration of a bisphosphonate for prophylaxis against osteoporosis.

Diet

No dietary restrictions exist, but patients with oral disease may benefit from avoiding foods, such as spicy foods, tomatoes, orange juice, and hard foods that may traumatize the oral epithelium mechanically, such as nuts, chips, and hard vegetables and fruit.

Activity

- Advise patients to minimize activities that traumatize the skin and that may precipitate blistering, such as contact sports. Nontraumatic exercises, such as swimming, may be helpful.
- Dental plates, dental bridges, or contact lenses may precipitate or exacerbate mucosal disease.

Medication

The aim of treatment is to reduce inflammatory response and autoantibody production. While target-specific therapy is not available, non-target-specific treatments currently are used. The most commonly used medications are corticosteroids.

The introduction of corticosteroids has reduced mortality greatly, but significant morbidity remains. Immunosuppressants should be considered early in the course of disease, as steroid-sparing agents. Mycophenolate mofetil and azathioprine are the usual first-line agents. Rituximab and intravenous immunoglobulin have also proved useful alone or in combination.²³ Cyclophosphamide is used for refractory disease. The role of biologic agents is being investigated. Each of these agents should be prescribed and monitored by physicians familiar with them. Wound care of erosions includes daily gentle cleaning, application of topical agents to promote wound healing, and use of nonadhesive dressings. The goal of wound care is to promote healing, minimize trauma to the surrounding skin, and diminish scarring.

Anti-inflammatory agents

Inhibit the inflammatory process by inhibiting specific cytokine production.

Prednisone (Deltasone, Meticorten, Orasone, Sterapred)

May decrease inflammation by reversing increased capillary permeability and suppressing PMN activity. Stabilizes lysosomal membranes and also suppresses lymphocytes and antibody production. For treating PV, administered PO and used alone or in combination with topical or intralesional steroids or in conjunction with other immunosuppressives.

In pediatric patients, disease management with this medication in consultation with the patient's pediatrician is advised.

Dosing

Adult

1-1.5 mg/kg/d PO initial every am or in divided doses; titrate dose to clinical response; 0.5-2 mg/kg/d; taper as condition improves; single morning dose is safer for long-term use, but divided doses have more anti-inflammatory effect

Pediatric

Administer as in adults

Interactions

Coadministration with estrogens may decrease prednisone clearance; when used with digoxin, digitalis toxicity secondary to hypokalemia may increase; phenobarbital, phenytoin, and rifampin may increase metabolism of glucocorticoids (consider increasing maintenance dose); monitor for hypokalemia with coadministration of diuretics

Contraindications

Documented hypersensitivity; viral infection, peptic ulcer disease, hepatic dysfunction, connective tissue infections, and fungal or tubercular skin infections; GI disease

Precautions

Pregnancy

B - Fetal risk not confirmed in studies in humans but has been shown in some studies in animals

Precautions

Abrupt discontinuation of glucocorticoids may cause adrenal crisis; peptic ulcer disease, hypokalemia, hyperglycemia, osteonecrosis, myopathy, osteoporosis, edema, euphoria, psychosis, myasthenia gravis, growth suppression, and infections may occur; qod therapy does not prevent bone loss

Immunosuppressive agents

Useful adjuvants in patients with PV with generalized disease unresponsive to steroids and/or other anti-inflammatory agents or in patients unable to tolerate prednisone.

Azathioprine (Imuran)

Antagonizes purine metabolism and inhibits synthesis of DNA, RNA, and proteins. May decrease proliferation of immune cells, which results in lower autoimmune activity. In conjunction with prednisone, it is more effective than prednisone alone. May be an effective monotherapy in mild cases, although the therapeutic effect is delayed 3-5 wk.

Consider withdrawal if no improvement within 3 mo.

Dosing

Adult

1 mg/kg/d qd/bid (empiric) or based on TPMT level (see Precautions); increase dose by 0.5 mg/kg/d after 6-8 wk if necessary; increase q4wk; 2 mg/kg/d maximum dose for most dermatologic purposes

Pediatric

Not established

Interactions

Allopurinol increases risk of pancytopenia; captopril/ACE inhibitors may increase risk of anemia and leukopenia; warfarin dose may need to be increased; pancuronium may need to be increase to achieve adequate paralysis; live virus vaccines, co-trimoxazole may increase risk of hematologic toxicity; rifampicin may cause transplant rejection; clozapine may increase risk of agranulocytosis

Contraindications

Absolute: Allergy to azathioprine, pregnancy or attempting pregnancy, clinically significant active infection

Relative: Concurrent use of allopurinol, prior treatment with alkylating agents (cyclophosphamide, chlorambucil, melphalan, others) because of high risk of neoplasia; pediatric patients (safety and efficacy in pediatric population not established)

Precautions

Pregnancy

D - Fetal risk shown in humans; use only if benefits outweigh risk to fetus

Precautions

TPMT testing is not entirely reliable but it involves testing activity of TPMT activity in RBCs, which correlates with systemic TPMT activity; functional enzyme test has been shown to have variability between test sites and the kits may contain varying amounts of enzyme inhibitor; starting at low doses, monitoring for pancytopenia, then increasing dose is an alternative; if clinical response is not good, patient may be homozygote for high activity and may need an increased dose; Wolverson *Comprehensive Dermatologic Drug Therapy*; other references recommend checking before treatment in all patients

TPMT <5 U: No treatment with azathioprine

TPMT 5-13.7 U: Dose not to exceed 0.5 mg/kg

TPMT 13.7-19 U: Dose not to exceed 1.5 mg/kg

TPMT >19 U: Dose not to exceed 2.5 mg/kg

Follow-up

Complications

- Secondary infection, which may be either systemic or localized to the skin, may occur because of the use of immunosuppressants and the presence of multiple erosions. Cutaneous infection delays wound healing and increases the risk of scarring.
- Malignancies resulting from immunosuppressants have been reported.
- Growth retardation has been reported in children taking systemic corticosteroids and immunosuppressants.
- Bone marrow suppression has been reported in patients receiving immunosuppressants. Increased incidence is reported of leukemia and lymphoma in patients receiving prolonged immunosuppression.

- Impaired immune responsiveness caused by corticosteroids and other immunosuppressive drugs may result in the rapid spread of infection. Corticosteroids suppress clinical signs of infection and may allow diseases such as septicemia or tuberculosis to reach an advanced stage before diagnosis.
- Osteoporosis may occur following the use of systemic corticosteroids.
- Adrenal insufficiency has been reported following prolonged use of glucocorticoids.

Prognosis

- The severity and natural history of pemphigus vulgaris (PV) are variable, but before the advent of steroids, most patients with PV died. Treatment with systemic steroids has reduced the mortality rate to 5-15%.
- Most deaths occur during the first few years of disease, and if the patient survives 5 years, the prognosis is good. Early disease probably is easier to control than widespread disease, and mortality may be higher if therapy is delayed.
- Morbidity and mortality are related to the extent of disease, the maximum dose of prednisolone required to induce remission, and the presence of other diseases. The outlook is worse in older patients and in patients with extensive disease.

Patient Education

- Minimize trauma to the skin because the patient's skin is fragile both from the disease and from the use of topical and systemic steroids.
- The patient's understanding of the disease and education is important because of the chronic nature of this disorder.
- Educate patients regarding their medications. They should know about dose, adverse effects, and symptoms of toxicity so they can report adverse effects to the physician.
- Educate patients about appropriate wound care.

Miscellaneous

Medicolegal Pitfalls

- Failure to secure the correct diagnosis using a compatible history and physical and appropriate testing. Routine histology and immunofluorescence should be performed to confirm the diagnosis and prior to treatment.
- Failure to explain adverse effects of treatment to patients on systemic therapy. Patients must be monitored appropriately for adverse effects, toxicity, and response to treatment.

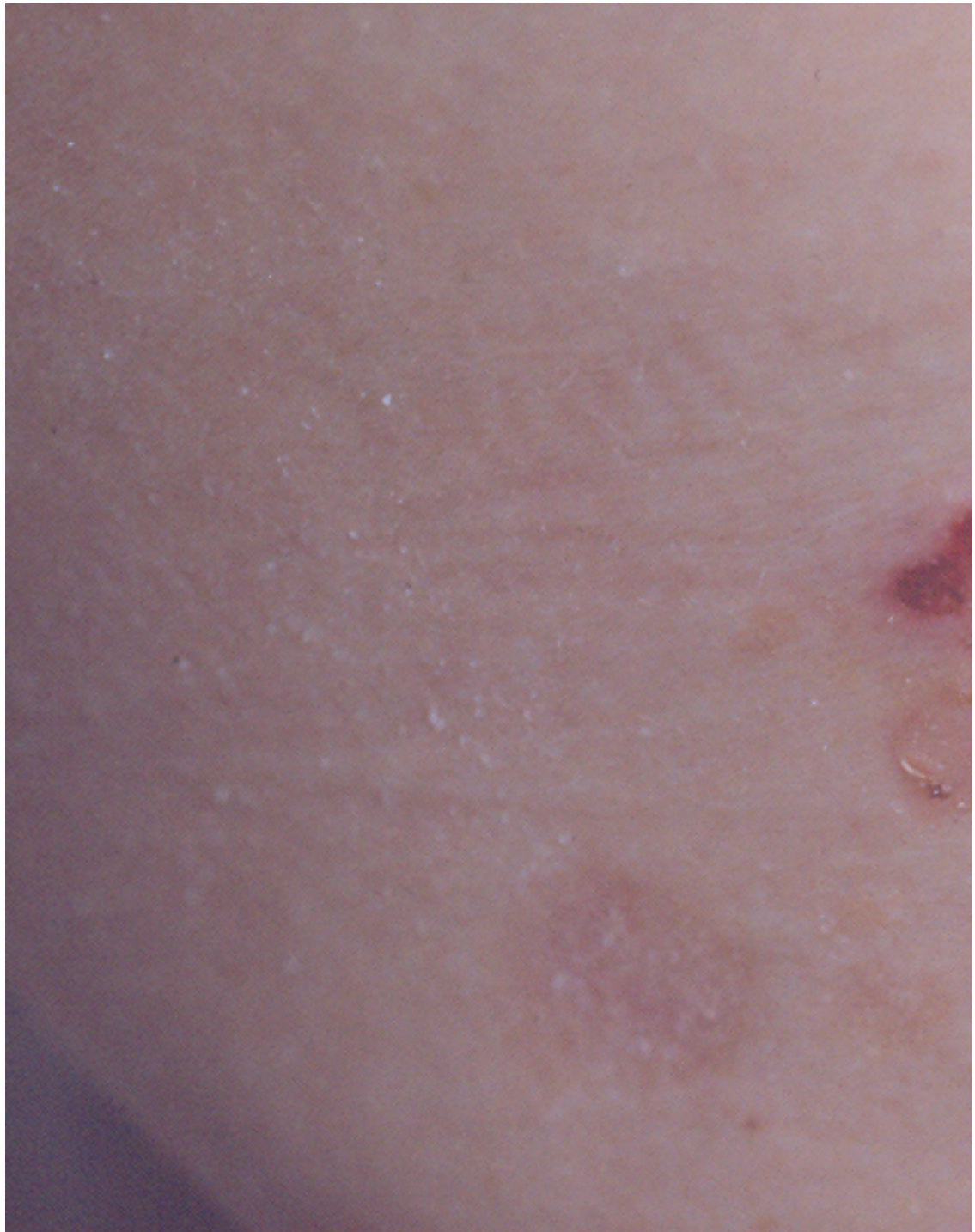
Special Concerns

- An accurate diagnosis is important before starting the treatment. Pemphigus vulgaris (PV) shares some common features with other autoimmune blistering diseases, which sometimes makes the diagnosis difficult. Criteria for diagnosis include the following:
 - Compatible clinical picture
 - Intra-dermal blistering disease confirmed by histopathology
 - Intercellular immunofluorescence throughout the epidermis of immunoglobulin and complement components confirmed by DIF and IDIF
- Physicians should educate patients about the disease, adverse effects, risks, drug interactions, and contraindications of the medications.
- Therapeutic regimen is chosen for each individual patient after assessing the risk and benefits for each medication.

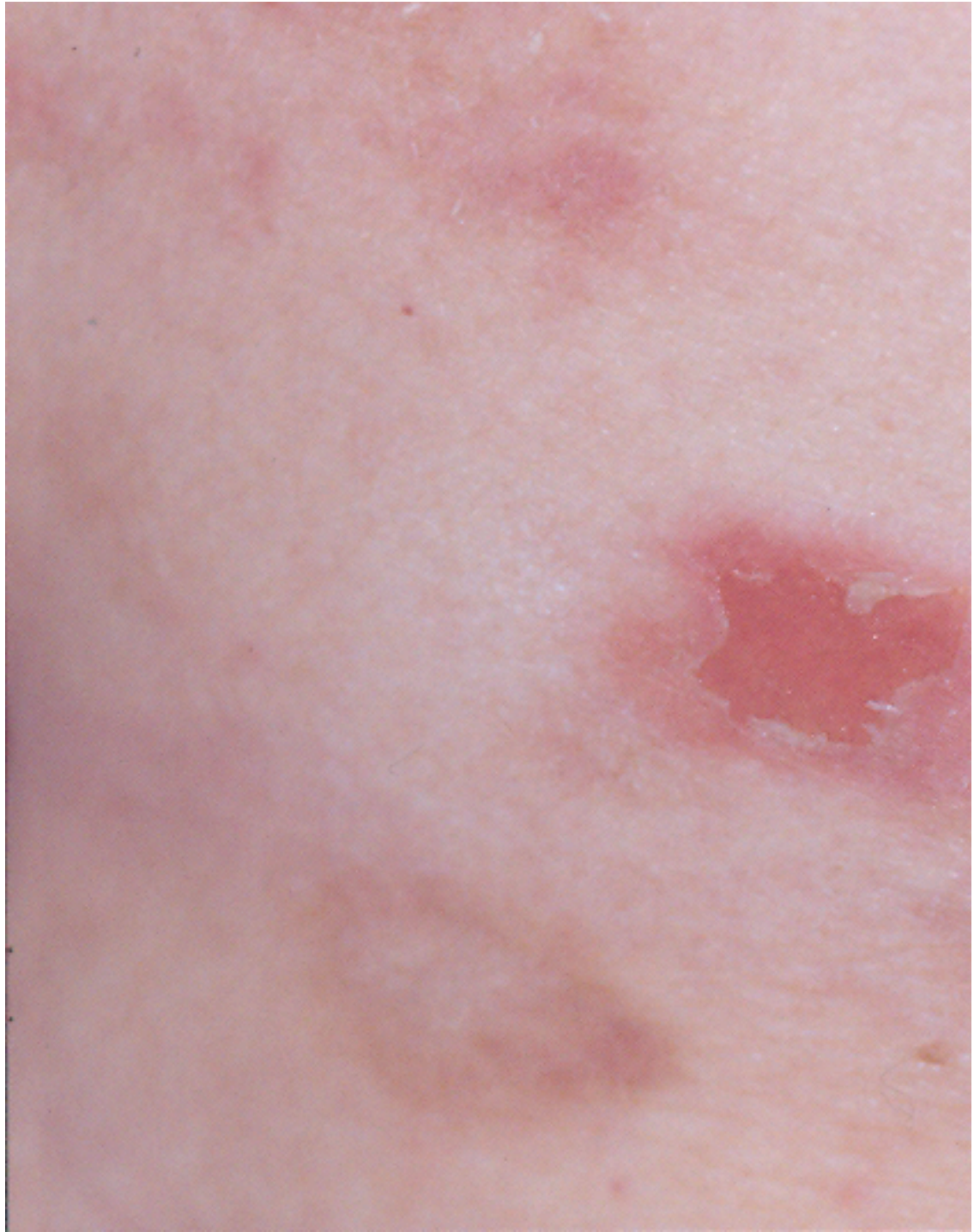Multimedia



Media file 1: Early, small blister filled with clear fluid arises on healthy skin.



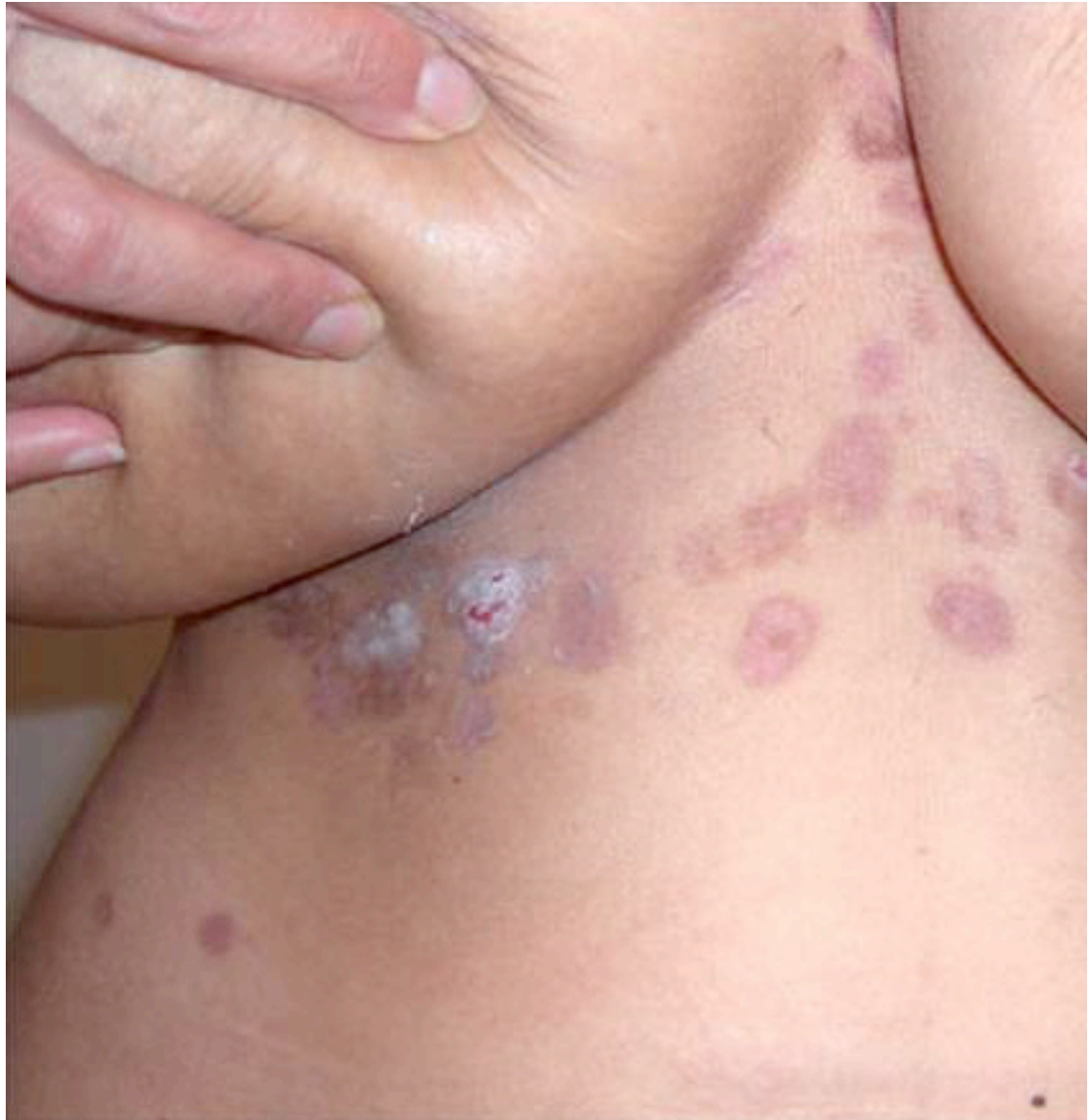Media file 2: Flaccid blister filled with clear fluid arises on healthy skin.



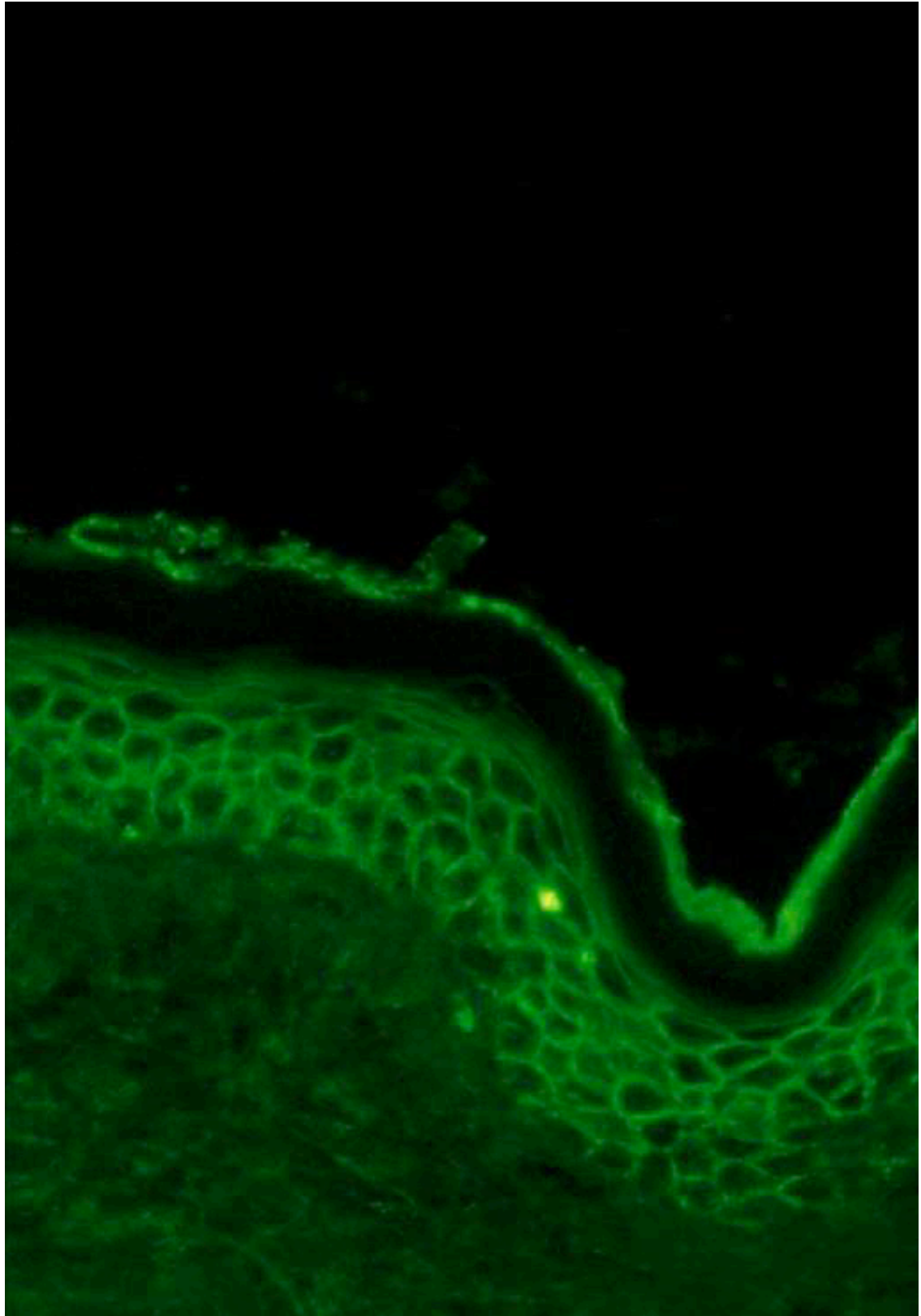
Media file 3: An erosion.



Media file 4: Erosions and healing areas on the back.



Media file 5: Healing areas on the chest and abdomen.



Media file 6: Direct immunofluorescence showing intercellular immunoglobulin G throughout the epidermis of a patient with pemphigus vulgaris.

References

45. Bhol K, Mohimen A, Ahmed AR. Correlation of subclasses of IgG with disease activity in pemphigus vulgaris. *Dermatology*. 1994;189 Suppl 1:85-9. [Medline].
46. Fitzpatrick RE, Newcomer VD. The correlation of disease activity and antibody titers in pemphigus. *Arch Dermatol*. Mar 1980;116(3):285-90. [Medline].
47. Pisanti S, Sharav Y, Kaufman E, Posner LN. Pemphigus vulgaris: incidence in Jews of different ethnic groups, according to age, sex, and initial lesion. *Oral Surg Oral Med Oral Pathol*. Sep 1974;38(3):382-7. [Medline].
48. Simon DG, Krutchkoff D, Kaslow RA, Zarbo R. Pemphigus in Hartford County, Connecticut, from 1972 to 1977. *Arch Dermatol*. Sep 1980;116(9):1035-7. [Medline].
49. Bastuji-Garin S, Souissi R, Blum L, et al. Comparative epidemiology of pemphigus in Tunisia and France: unusual incidence of pemphigus foliaceus in young Tunisian women. *J Invest Dermatol*. Feb 1995;104(2):302-5. [Medline].
50. Hietanen J, Salo OP. Pemphigus: an epidemiological study of patients treated in Finnish hospitals between 1969 and 1978. *Acta Derm Venereol*. 1982;62(6):491-6. [Medline].
51. Wilson C, Wojnarowska F, Mehra NK, Pasricha JS. Pemphigus in Oxford, UK, and New Delhi, India: a comparative study of disease characteristics and HLA antigens. *Dermatology*. 1994;189 Suppl 1:108-10. [Medline].
52. Goldberg I, Ingher A, Brenner S. Pemphigus vulgaris triggered by rifampin and emotional stress. *Skinmed*. Sep-Oct 2004;3(5):294. [Medline].
53. Hodak E, Kremer I, David M, et al. Conjunctival involvement in pemphigus vulgaris: a clinical, histopathological and immunofluorescence study. *Br J Dermatol*. Nov 1990;123(5):615-20. [Medline].
54. Trattner A, Lurie R, Leiser A, et al. Esophageal involvement in pemphigus vulgaris: a clinical, histologic, and immunopathologic study. *J Am Acad Dermatol*. Feb 1991;24(2 Pt 1):223-6. [Medline].
55. Berker DD, Dalziel K, Dawber RP, Wojnarowska F. Pemphigus associated with nail dystrophy. *Br J Dermatol*. Oct 1993;129(4):461-4. [Medline].
56. Engineer L, Norton LA, Ahmed AR. Nail involvement in pemphigus vulgaris. *J Am Acad Dermatol*. Sep 2000;43(3):529-35. [Medline].
57. Hern S, Vaughan Jones SA, Setterfield J, et al. Pemphigus vulgaris in pregnancy with favourable foetal prognosis. *Clin Exp Dermatol*. Nov 1998;23(6):260-3. [Medline].
58. Firooz A, Mazhar A, Ahmed AR. Prevalence of autoimmune diseases in the family members of patients with pemphigus vulgaris. *J Am Acad Dermatol*. Sep 1994;31(3 Pt 1):434-7. [Medline].
59. Ahmed AR, Wagner R, Khatri K, et al. Major histocompatibility complex haplotypes and class II genes in non-Jewish patients with pemphigus vulgaris. *Proc Natl Acad Sci U S A*. Jun 1 1991;88(11):5056-60. [Medline].
60. Lombardi ML, Mercurio O, Ruocco V, et al. Common human leukocyte antigen alleles in pemphigus vulgaris and pemphigus foliaceus Italian patients. *J Invest Dermatol*. Jul 1999;113(1):107-10. [Medline].
61. Reohr PB, Manglabruks A, Janiga AM, et al. Pemphigus vulgaris in siblings: HLA-DR4 and HLA-DQw3 and susceptibility to pemphigus. *J Am Acad Dermatol*. Aug 1992;27(2 Pt 1):189-93. [Medline].
62. Szafer F, Brautbar C, Tzofoni E, et al. Detection of disease-specific restriction fragment length polymorphisms in pemphigus vulgaris linked to the DQw1 and DQw3 alleles of the HLA-D region. *Proc Natl Acad Sci U S A*. Sep 1987;84(18):6542-5. [Medline].
63. Cruz PD Jr, Coldiron BM, Sontheimer RD. Concurrent features of cutaneous lupus erythematosus and pemphigus erythematosus following myasthenia gravis and thymoma. *J Am Acad Dermatol*. Feb 1987;16(2 Pt 2):472-80. [Medline].
64. Judd KP, Lever WF. Correlation of antibodies in skin and serum with disease severity in pemphigus. *Arch Dermatol*. Apr 1979;115(4):428-32. [Medline].
65. Tabrizi M, Chams-Davatchi C, Esmaeeli N, et al. Accelerating effects of epidermal growth factor on skin lesions of pemphigus vulgaris: a double-blind, randomized, controlled trial. *J Eur Acad Dermatol Venereol*. Jan 2007;21(1):79-84. [Medline].
66. [Best Evidence] Amagai M, Ikeda S, Shimizu H, et al. A randomized double-blind trial of intravenous immunoglobulin for pemphigus. *J Am Acad Dermatol*. Apr 2009;60(4):595-603. [Medline].
67. Ahmed AR, Spigelman Z, Cavacini LA, Posner MR. Treatment of pemphigus vulgaris with rituximab and intravenous immune globulin. *N Engl J Med*. Oct 26 2006;355(17):1772-9. [Medline].

68. Aberer W, Wolff-Schreiner EC, Stingl G, Wolff K. Azathioprine in the treatment of pemphigus vulgaris. A long-term follow-up. *J Am Acad Dermatol*. Mar 1987;16(3 Pt 1):527-33. [Medline].
69. Ahmed AR, Moy R. Death in pemphigus. *J Am Acad Dermatol*. Aug 1982;7(2):221-8. [Medline].
70. Amagai M, Klaus-Kovtun V, Stanley JR. Autoantibodies against a novel epithelial cadherin in pemphigus vulgaris, a disease of cell adhesion. *Cell*. Nov 29 1991;67(5):869-77. [Medline].
71. Anhalt GJ, Díaz LA. Pemphigus vulgaris—a model for cutaneous autoimmunity. *J Am Acad Dermatol*. Jul 2004;51(1 Suppl):S20-1. [Medline].
72. Asarch A, Razzaque Ahmed A. Treatment of juvenile pemphigus vulgaris with intravenous immunoglobulin therapy. *Pediatr Dermatol*. Mar-Apr 2009;26(2):197-202. [Medline].
73. Ayoub N. [Pemphigus and pemphigus-triggering drugs]. *Ann Dermatol Venereol*. Jun-Jul 2005;132(6-7 Pt 1):595. [Medline].
74. Bakos L, Zoratto G, Brunetto L, Mazzotti N, Cartell A. Photodynamic therapy: a useful adjunct therapy for recalcitrant ulceration in pemphigus vulgaris. *J Eur Acad Dermatol Venereol*. May 2009;23(5):599-600. [Medline].
75. Baskan EB, Yilmaz M, Tunali S, Saricaoglu H. Efficacy and safety of long-term mycophenolate sodium therapy in pemphigus vulgaris. *J Eur Acad Dermatol Venereol*. Mar 17 2009; [Medline].
76. Bystryn JC, Jiao D. IVIg selectively and rapidly decreases circulating pathogenic autoantibodies in pemphigus vulgaris. *Autoimmunity*. Nov 2006;39(7):601-7. [Medline].
77. Bystryn JC, Moore MM. Cutaneous pemphigus vulgaris: what causes it?. *J Am Acad Dermatol*. Jul 2006;55(1):175-6; author reply 176-7. [Medline].
78. Bystryn JC, Steinman NM. The adjuvant therapy of pemphigus. An update. *Arch Dermatol*. Feb 1996;132(2):203-12. [Medline].
79. Carson PJ, Hameed A, Ahmed AR. Influence of treatment on the clinical course of pemphigus vulgaris. *J Am Acad Dermatol*. Apr 1996;34(4):645-52. [Medline].
80. Chams-Davatchi C, Daneshpazhoo M. Prednisolone dosage in pemphigus vulgaris. *J Am Acad Dermatol*. Sep 2005;53(3):547. [Medline].
81. Dmochowski M, Hashimoto T, Amagai M, et al. The extracellular aminoterminal domain of bovine desmoglein 1 (Dsg1) is recognized only by certain pemphigus foliaceus sera, whereas its intracellular domain is recognized by both pemphigus vulgaris and pemphigus foliaceus sera. *J Invest Dermatol*. Aug 1994;103(2):173-7. [Medline].
82. Dmochowski M, Hashimoto T, Chidgey MA, et al. Demonstration of antibodies to bovine desmocollin isoforms in certain pemphigus sera. *Br J Dermatol*. Oct 1995;133(4):519-25. [Medline].
83. El Tal AK, Posner MR, Spigelman Z, Ahmed AR. Rituximab: a monoclonal antibody to CD20 used in the treatment of pemphigus vulgaris. *J Am Acad Dermatol*. Sep 2006;55(3):449-59. [Medline].
84. el-Darouti M, Marzouk S, Abdel Hay R, el-Tawdy A, Fawzy M, Leheta T, et al. The use of sulfasalazine and pentoxifylline (low-cost antitumour necrosis factor drugs) as adjuvant therapy for the treatment of pemphigus vulgaris: a comparative study. *Br J Dermatol*. Aug 2009;161(2):313-9. [Medline].
85. Elder D, Elenitsas R, Jaworsky C, Johnson BL. Pemphigus vulgaris. In: *Lever's Histopathology of the Skin*. 8th ed. Lippincott Williams & Wilkins; 1997:218-50.
86. Ettlin DA. Pemphigus. *Dent Clin North Am*. Jan 2005;49(1):107-25, viii-ix. [Medline].
87. Fatourech MM, El-Azhary RA, Gibson LE. Rituximab: Applications in dermatology. *Int J Dermatol*. Oct 2006;45(10):1143-55. [Medline].
88. Grando SA, Glukhenky BT, Drannik GN, et al. Mediators of inflammation in blister fluids from patients with pemphigus vulgaris and bullous pemphigoid. *Arch Dermatol*. Jul 1989;125(7):925-30. [Medline].
89. Grando SA, Terman AK, Stupina AS, et al. Ultrastructural study of clinically uninvolved skin of patients with pemphigus vulgaris. *Clin Exp Dermatol*. Sep 1991;16(5):359-63. [Medline].
90. Green MG, Bystryn JC. Effect of intravenous immunoglobulin therapy on serum levels of IgG1 and IgG4 antidesmoglein 1 and antidesmoglein 3 antibodies in pemphigus vulgaris. *Arch Dermatol*. Dec 2008;144(12):1621-4. [Medline].
91. [Guideline] Harman KE, Albert S, Black MM. Guidelines for the management of pemphigus vulgaris. *Br J Dermatol*. Nov 2003;149(5):926-37. [Medline].
92. Hashimoto T. Recent advances in the study of the pathophysiology of pemphigus. *Arch Dermatol Res*. Apr 2003;295 Suppl 1:S2-11. [Medline].

93. Hashimoto T, Ogawa MM, Konohana A, Nishikawa T. Detection of pemphigus vulgaris and pemphigus foliaceus antigens by immunoblot analysis using different antigen sources. *J Invest Dermatol.* Mar 1990;94(3):327-31. [\[Medline\]](#).
94. Helander SD, Rogers RS 3rd. The sensitivity and specificity of direct immunofluorescence testing in disorders of mucous membranes. *J Am Acad Dermatol.* Jan 1994;30(1):65-75. [\[Medline\]](#).
95. Jackson AP, Hall AG, McLelland J. Thiopurine methyltransferase levels should be measured before commencing patients on azathioprine. *Br J Dermatol.* Jan 1997;136(1):133-4. [\[Medline\]](#).
96. Jin P, Shao C, Ye G. Chronic bullous dermatoses in China. *Int J Dermatol.* Feb 1993;32(2):89-92. [\[Medline\]](#).
97. Kawana S, Geoghegan WD, Jordon RE, Nishiyama S. Deposition of the membrane attack complex of complement in pemphigus vulgaris and pemphigus foliaceus skin. *J Invest Dermatol.* Apr 1989;92(4):588-92. [\[Medline\]](#).
98. Kirtschig G, Wojnarowska F. Autoimmune blistering diseases: an up-date of diagnostic methods and investigations. *Clin Exp Dermatol.* Mar 1994;19(2):97-112. [\[Medline\]](#).
99. Korman NJ. Pemphigus. *Dermatol Clin.* Oct 1990;8(4):689-700. [\[Medline\]](#).
100. Krain LS. Pemphigus. Epidemiologic and survival characteristics of 59 patients, 1955-1973. *Arch Dermatol.* Dec 1974;110(6):862-5. [\[Medline\]](#).
101. Loo WJ, Burrows NP. Management of autoimmune skin disorders in the elderly. *Drugs Aging.* 2004;21(12):767-77. [\[Medline\]](#).
102. Marren P, Wojnarowska F, Venning V, et al. Vulvar involvement in autoimmune bullous diseases. *J Reprod Med.* Feb 1993;38(2):101-7. [\[Medline\]](#).
103. Matzner Y, Erlich HA, Brautbar C, et al. Identical HLA class II alleles predispose to drug-triggered and idiopathic pemphigus vulgaris. *Acta Derm Venereol.* Jan 1995;75(1):12-4. [\[Medline\]](#).
104. Mentink LF, de Jong MC, Kloosterhuis GJ, et al. Coexistence of IgA antibodies to desmogleins 1 and 3 in pemphigus vulgaris, pemphigus foliaceus and paraneoplastic pemphigus. *Br J Dermatol.* Jan 29 2007;[\[Medline\]](#).
105. Mimouni D, Nousari CH, Cummins DL, et al. Differences and similarities among expert opinions on the diagnosis and treatment of pemphigus vulgaris. *J Am Acad Dermatol.* Dec 2003;49(6):1059-62. [\[Medline\]](#).
106. Mittmann N, Chan B, Knowles S, et al. Effect of intravenous immunoglobulin on prednisone dose in patients with pemphigus vulgaris. *J Cutan Med Surg.* Sep-Oct 2006;10(5):222-7. [\[Medline\]](#).
107. Mydlarski PR, Ho V, Shear NH. Canadian consensus statement on the use of intravenous immunoglobulin therapy in dermatology. *J Cutan Med Surg.* Sep-Oct 2006;10(5):205-21. [\[Medline\]](#).
108. Rosenberg FR, Sanders S, Nelson CT. Pemphigus: a 20-year review of 107 patients treated with corticosteroids. *Arch Dermatol.* Jul 1976;112(7):962-70. [\[Medline\]](#).
109. Savin JA. Some factors affecting prognosis in pemphigus vulgaris and pemphigoid. *Br J Dermatol.* Apr 1981;104(4):415-20. [\[Medline\]](#).
110. Schmidt E, Hunzelmann N, Zillikens D, et al.